

### TECHNOLOGY HISTORY

For over 130 years, Toshiba has been a world leader in developing technology to improve the quality of life. Our 50,000 global patents demonstrate a long, rich history of leading innovation. It might surprise you to learn about some of the things we've invented.

<b>1915</b> Japan's first X-ray tube	<b>1990</b> First helical CT scanner	<b>2002</b> First 400 ms CT scanner
<b>1954</b> First digital computer	<b>1993</b> First real-time CT fluoro	<b>2007</b> First <b>dynamic volume CT</b> scanner
<b>1977</b> First cardiac ultrasound scanner	<b>1995</b> First DVD	<b>2009</b> First 160-row Helical
<b>1985</b> First slip-ring CT scanner	<b>1999</b> First quiet MRI	<b>2010</b> First iterative recon technique for 320 Detector Row CT
<b>1986</b> First laptop computer	<b>1999</b> First 0.5 mm multidetector CT	<b>2011</b> First 80 detector row CT scanner

WARNING: Any reference to x-ray exposure, intravenous contrast dosage, and other medication is intended as a reference guideline only. The guidelines in this document do not substitute for the judgment of a healthcare provider. Each scan requires medical judgment by the healthcare provider about exposing the patient to ionizing radiation. Use the As Low As Reasonably Achievable radiation dose principle to balance factors such as the patient's condition, size and age; region to be imaged; and diagnostic task.

Due to local regulatory processes, some of the products included in this brochure may not be available in each country. Please contact your local Toshiba sales representative for the most current information.



TOSHIBA MEDICAL SYSTEMS CORPORATION

<http://www.toshibamedicalsystems.com>

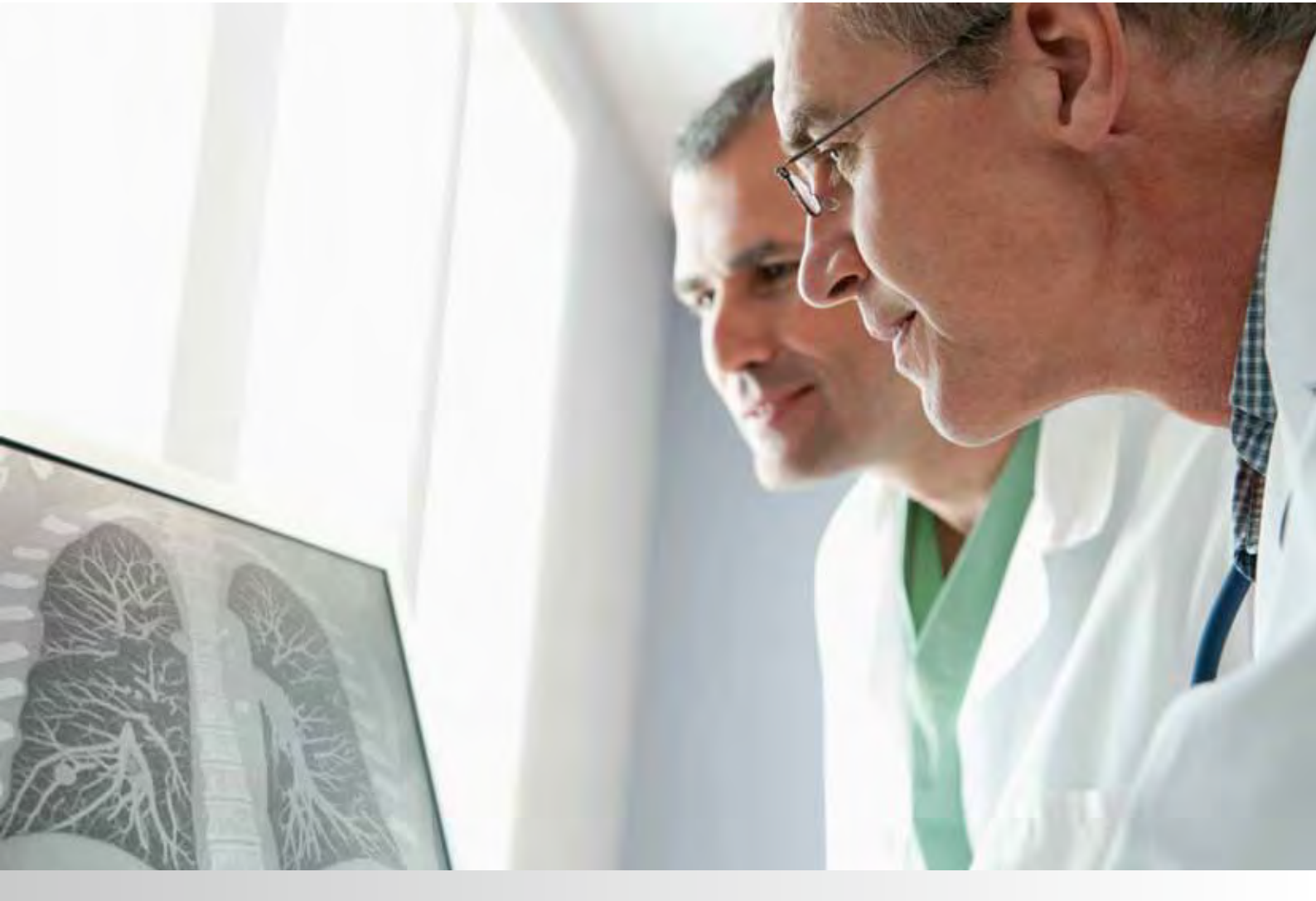
©Toshiba Medical Systems Corporation 2012 all rights reserved.  
Design and specifications subject to change without notice.  
MCACT0220EA 2012-02 TME/D

Toshiba Medical Systems Corporation meets internationally recognized standards for Quality Management System ISO 9001, ISO 13485.

Toshiba Medical Systems Corporation Nasu Operations meets the Environmental Management System standard, ISO 14001.

Made for Life, Aquilion ONE, <sup>SURE</sup>Exposure and <sup>SURE</sup>Subtraction are trademarks of Toshiba Medical Systems Corporation.

Printed in Japan



Adaptive Iterative Dose Reduction in 3D

Save dose in seconds, not minutes



Because everyone deserves the best diagnosis  
at the lowest dose.



Dear Reader,

The balance of image quality and radiation dose is the fundamental challenge for physicians in performing routine clinical examinations while adhering to the ALARA principle. However, it is difficult to determine the optimal exposure for a patient based on size, weight, or shape alone. The task of manually determining the exposure in combination with advanced iterative dose reduction methods only becomes more complex.

To meet these challenges, Toshiba has developed <sup>SURE</sup>Exposure™ 3D Adaptive, which accurately adjusts X-ray exposure based on the desired reference image quality. The exposure parameters are automatically weighted to compensate for large patients in whom a small increase in image noise is acceptable. Even the detector output settings are fine-tuned for each patient to maximize the resultant signal strength, ensuring optimal image quality.

AIDR 3D is an advanced iterative reconstruction algorithm that reduces noise in the 3-dimensional raw data domain and in the reconstruction process. With the integration of AIDR 3D into <sup>SURE</sup>Exposure, radiation exposure is automatically reduced by up to 75% before the scan, ensuring that the lowest dose is employed for the specific diagnostic objective irrespective of the size or shape of the patient.

The results of these development efforts will help to ensure that Toshiba users enjoy examinations of consistent quality at the lowest dose needed to ensure an accurate diagnosis.

Sincerely,



Yasuo Nobuta  
Vice President  
General Manager CT Systems Division  
Toshiba Medical Systems Corporation



## Table of contents

Adaptive Iterative Dose Reduction in 3D	6
Dose Reduction in Seconds	8
Cardiac 0.4 mSv	10
Neck Subtraction	12
Tetralogy of Fallot	14
Renal CT Angiogram	16
Chest Pain	18
Renal Colic	20
Lung Tumor	24
Myocardial Bridging	26
Cervical Spine	28
Polycystic Disease	30
Impacted Fracture	32
Lung Metastasis	34
Facial Bones	36
Shoulder Arthrogram	38
CT Urography	40



# Adaptive Iterative Dose Reduction in 3D

Adaptive Iterative Dose Reduction in 3D (AIDR 3D) is the latest evolution of iterative reconstruction technology that has been fully integrated into the imaging chain to ensure automatic dose reduction for all your CT examinations.

## INTEGRATED DOSE REDUCTION

Minimizing radiation dose is without doubt a major concern to all medical imaging practitioners. Since patients come in all shapes and sizes, automatic exposure control systems have proven to be very useful in maintaining diagnostic image quality at a radiation dose suitable for each patient. It is therefore imperative that exposure control systems automatically react to dose reduction technology where made available to the user.

Toshiba's <sup>SURE</sup>Exposure 3D Adaptive exposure control system is fully integrated into the imaging chain and can therefore calculate the minimum radiation exposure required for each examination in every patient. With the inclusion of AIDR 3D in the scan protocol, the calculated exposure is automatically reduced by up to 75% as compared to a scan performed with traditional filtered backprojection reconstruction.

## <sup>SURE</sup>EXPOSURE 3D ADAPTIVE

<sup>SURE</sup>Exposure 3D Adaptive begins by measuring the patient attenuation from the scanogram, which serves as an accurate model of patient size and absorption characteristics in 3D.

Each <sup>SURE</sup>Exposure 3D Adaptive preset includes a reference level of image quality for the specific diagnostic objective. Clinically however, larger patients contain more inherent contrast and can be diagnosed with slightly higher noise levels. Therefore, the reference image quality is automatically adapted to patient size, ensuring diagnostic quality and minimizing radiation dose.

Based on the patient size-adapted reference image quality and measured absorption, the X-ray exposure is calculated for modulation in the X, Y and Z planes to ensure consistent low-dose diagnostic image quality for the entire scan.

## AIDR 3D RECONSTRUCTION

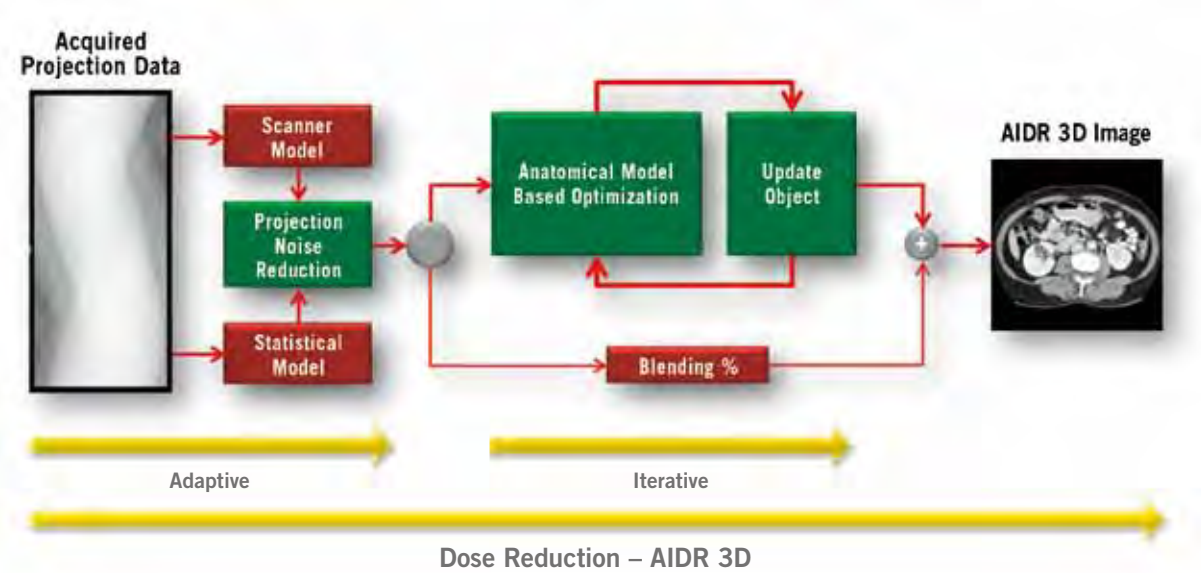

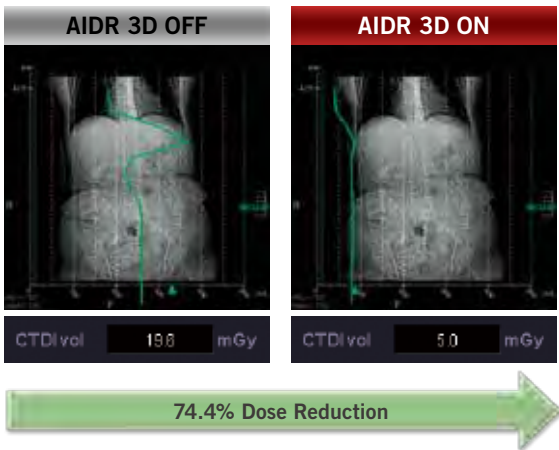
Once the scan has been performed with low-dose parameters, automatic reconstruction with AIDR 3D is performed. This advanced iterative reconstruction algorithm works in two parts. The first part adaptively removes photon noise in the 3D raw data domain. This is followed by the second part, model-based iterative noise reduction in the reconstruction process.

The low-dose raw data will have an inherently low signal-to-noise ratio. AIDR 3D is able to adaptively apply 3D noise reduction based on the actual scanning conditions and the electronic and quantum noise statistics. In this way, the maximum signal is preserved while noise and artifact-producing signals are dramatically reduced. From this noise-reduced raw data, primary reconstruction is then performed.

AIDR 3D then applies an iterative data enhancement algorithm in the reconstruction domain. This algorithm adapts to different organs and reconstruction kernels, which ensures that maximum noise reduction is achieved without compromising spatial resolution.

The final process involves an adaptive blending of the iterative reconstruction and the primary reconstruction to create the AIDR 3D image. This blending ensures that AIDR 3D images retain a natural appearance even though they are acquired at significantly lower dose.

Fully integrated into scan parameter selection and the reconstruction process, AIDR 3D delivers robust dose reduction for all your patients.



Schematic of the AIDR 3D algorithm

# Dose Reduction in Seconds

Truly groundbreaking dose reduction technology must be fast enough to fit into busy workflow schedules. AIDR 3D reconstruction has therefore been systematically optimized to minimize the impact on patient throughput. As a result, advanced iterative reconstruction with AIDR 3D adds mere seconds to the total reconstruction time.

## AIDR 3D PERFORMANCE

The exact reconstruction time for any given examination depends on many factors, including the acquisition slice thickness and pitch settings. So let's look at a real-life clinical scenario.

As a typical example, consider an abdominal CT scan performed using the Aquilion ONE™ with a 160-row Ultra Helical acquisition. The preprogrammed reconstructions include a volume of overlapping 0.5 mm/0.25 mm slices, resulting in 1600 images.

Reconstruction with AIDR 3D requires just 6 seconds more than the same reconstruction performed with traditional filtered backprojection.

In this scenario, just a few seconds of additional reconstruction time is all that is needed for a dramatic dose reduction of up to 75%. In addition, reconstruction is performed in parallel with scanning, resulting in seamless workflow and high patient throughput.

## AIDR 3D INTEGRATED

Three selectable strengths of AIDR 3D are provided to suit all your clinical needs. Mild, Standard, and Strong presets provide increasing levels of noise reduction. Based on feedback from a wide variety of customers, the AIDR 3D Standard parameter has been integrated into all routine examinations, and the Strong parameter is used for ultra-low-dose dynamic volume scans, including perfusion.

The positive response from our customers reflects the fact that AIDR 3D is an advanced iterative reconstruction technique which is fully integrated into the imaging chain and can provide dramatic dose reduction for all patients. In addition, the AIDR 3D reconstructions maintain a natural appearance. The cost is only a few additional seconds in total reconstruction time.

AIDR 3D is a standard feature in all newly introduced Toshiba CT systems because we believe that reducing patient dose should not come with a price tag.



Dr. John Troupis

Co-Unit Head of Cardiac CT  
Diagnostic Imaging, Southern Health  
Australia

The Toshiba solution for iterative reconstruction technology (AIDR 3D) has proven to be an effective method for reducing patient dose for every routine clinical examination performed on our CT system. AIDR 3D works to reduce image noise by up to 50% while maintaining spatial resolution, which is an impressive development. Reduced noise in the reconstructed images permits reduced radiation dose to achieve a similar level of diagnostic image quality. In our clinical setting, dose reduction of up to 75% is achieved routinely as AIDR 3D is integrated into the automatic exposure control software, which prospectively calculates the tube current for each examination based on our preferred reference image quality. Quite simply there is no guesswork needed, and the perfect balance of image quality at reduced dose is completely automated with consistent results.

The comprehensive dose reduction solution offered by Toshiba was implemented into our routine clinical practice during the first morning the software was introduced. The additional reconstruction time that is required by the iterative technique is measured in mere seconds, which has had no impact on our clinical workflow.

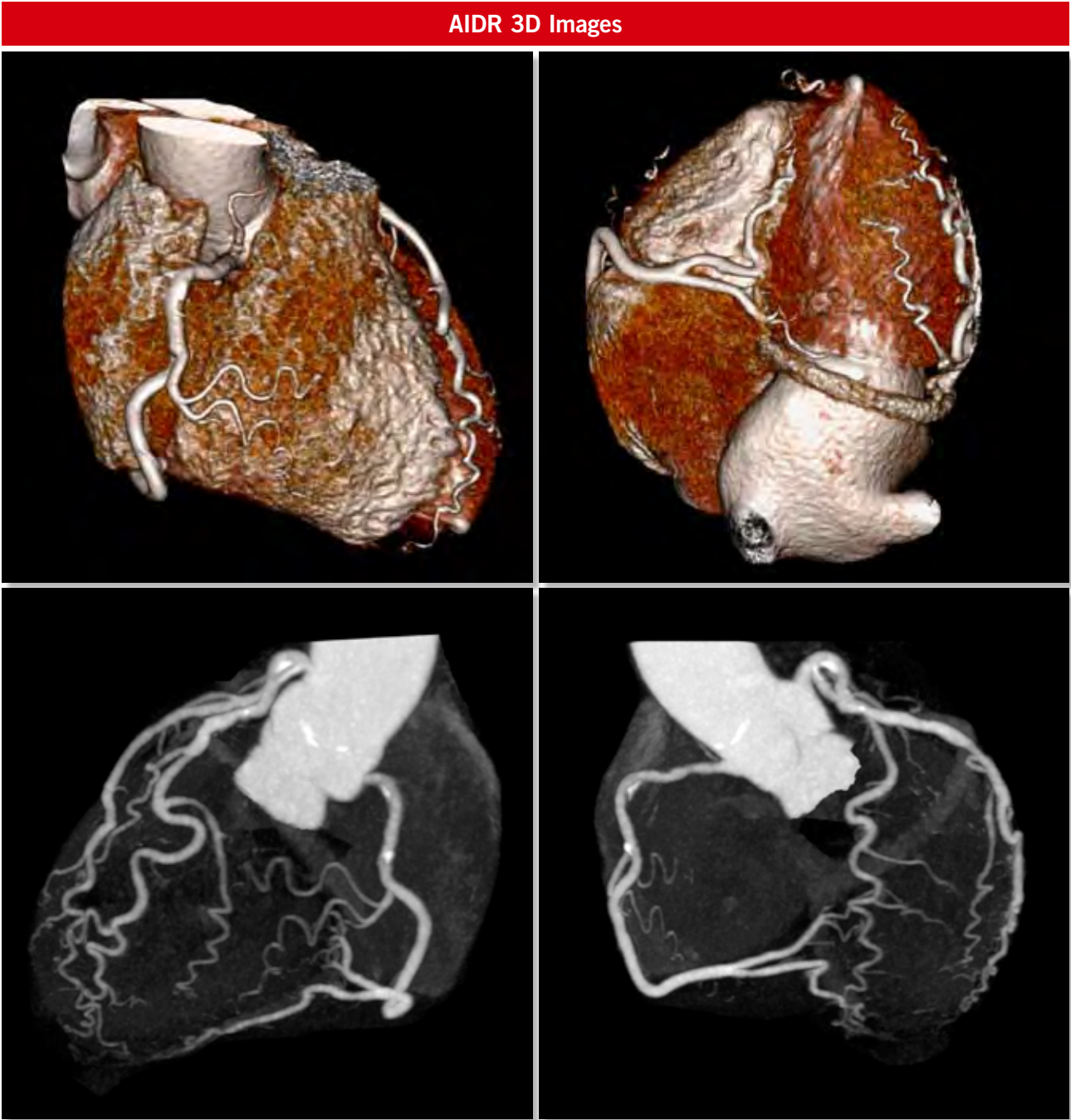
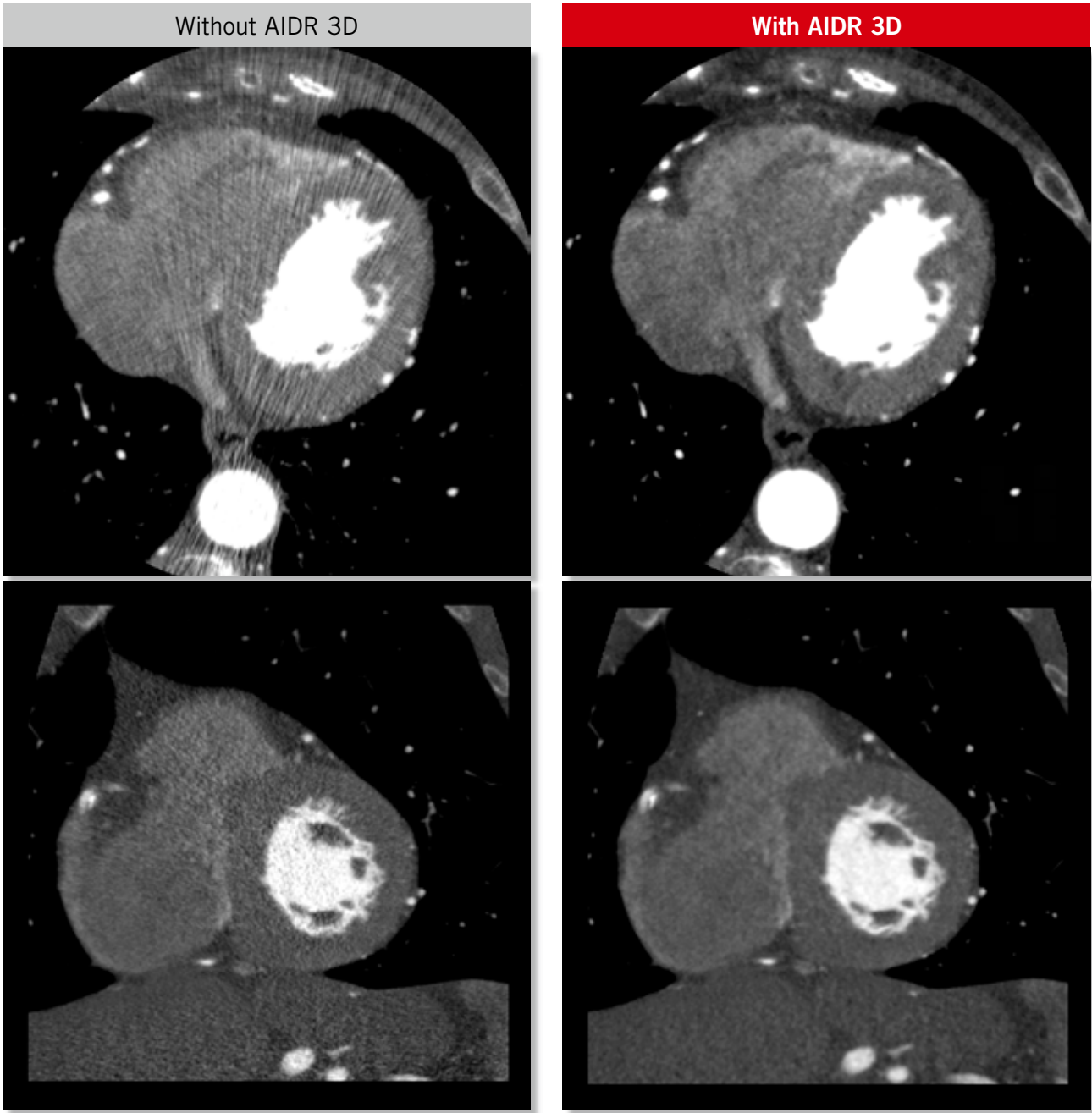
I have seen a lot of advances in CT technology over the years that have expanded the clinical utility of CT, and now we have advanced technology that is dramatically increasing patient safety.

Cardiac 0.4 mSv

Scan Mode	Collimation	Pitch	kVp	mAs	Rotation time (s)	Scan range (mm)	Dose Reduction	CTDI vol (mGy)	DLP (mGy-cm)	Effective Dose (mSv)	K
Volume	0.5 mm x 280	na	80	<sup>SURE</sup> Exposure Cardiac	0.35	140	AIDR 3D Standard	2.1	29.0	0.4	0.014

Clinical Description:

This 75-year-old woman with a BMI of 20 showed abnormal results in a stress echocardiography examination. Several calcified plaques are demonstrated, but no significant stenosis is seen. This scan performed at 80 kV shows excellent image quality with AIDR 3D reconstruction.





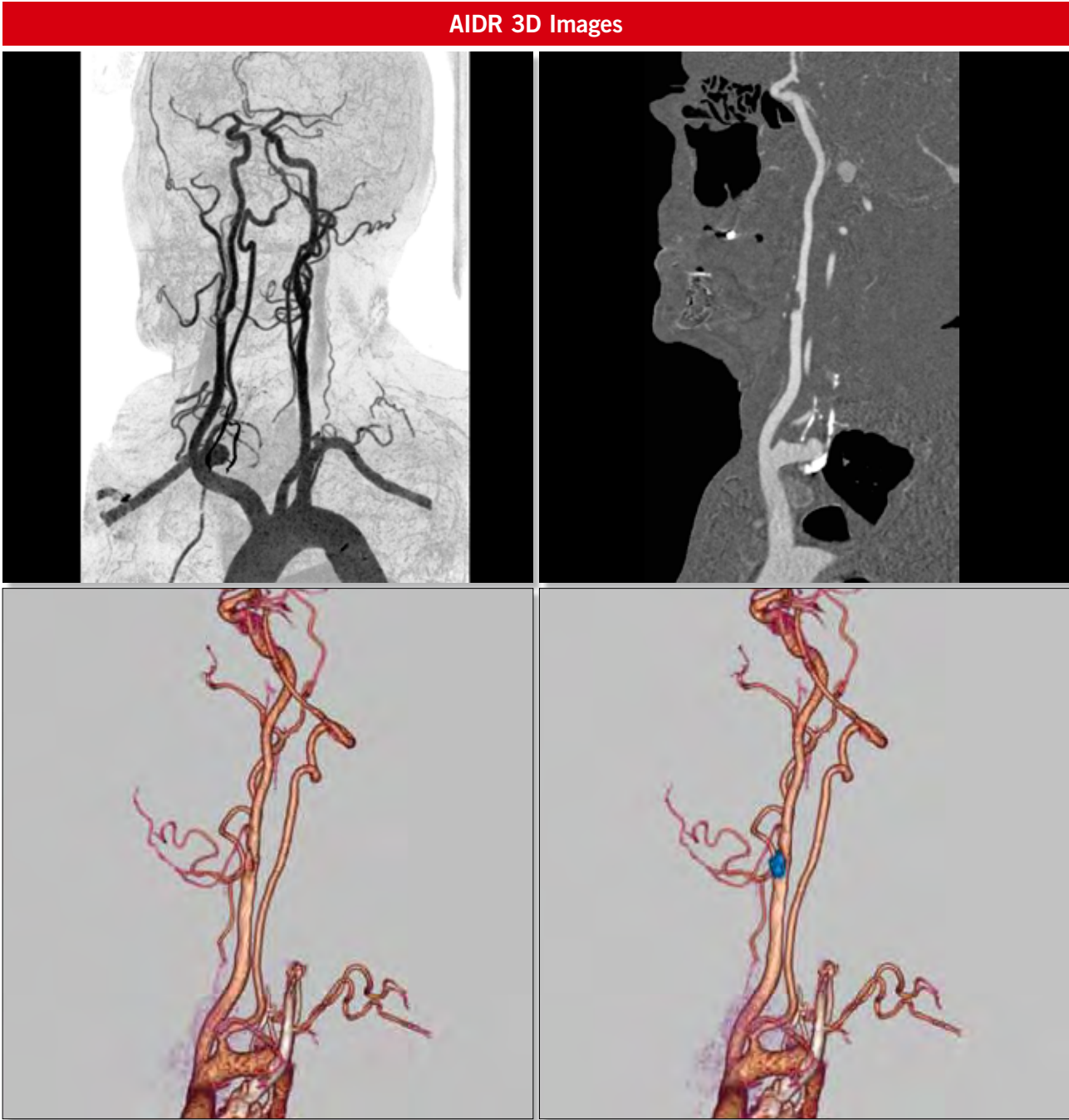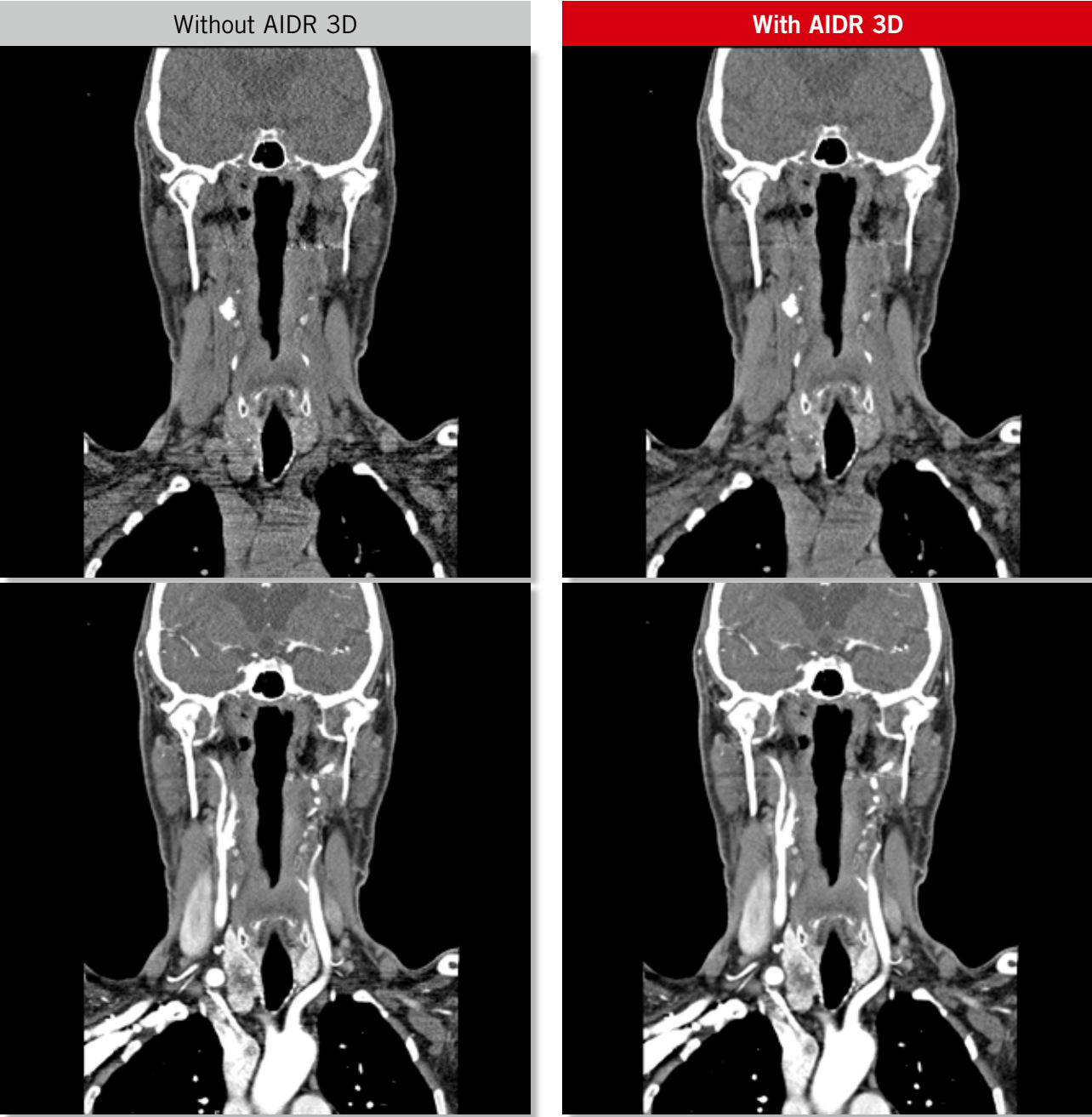Neck Subtraction

	Scan Mode	Collimation	Pitch	kVp	mAs	Rotation time (s)	Scan range (mm)	Dose Reduction	CTDI vol (mGy)	DLP (mGy-cm)	Effective Dose (mSv)	K
Pre Contrast	Helical	0.5 mm x 100	0.87	120	<sup>SURE</sup> Exposure Low Dose	0.5	312	AIDR 3D Standard	2.9	109.7	0.60	0.0054
Post Contrast	Helical	0.5 mm x 100	0.87	120	<sup>SURE</sup> Exposure Quality	0.5	312	AIDR 3D Standard	6.3	240.2	1.3	0.0054

Clinical Description:

This 81-year-old man presented with left-sided facial droop and hemiparesis. An initial CT brain scan was negative. Subtraction CTA of the carotid arterial circulation was requested.

<sup>SURE</sup>Subtraction™ software employs a deformable registration algorithm to ensure accurate registration and subtraction of the bones and calcified plaque, permitting excellent visualization of the carotid and vertebral arteries. The calcified plaque at the bifurcation of the right carotid artery is perfectly subtracted to reveal a stenosis of approximately 75%.



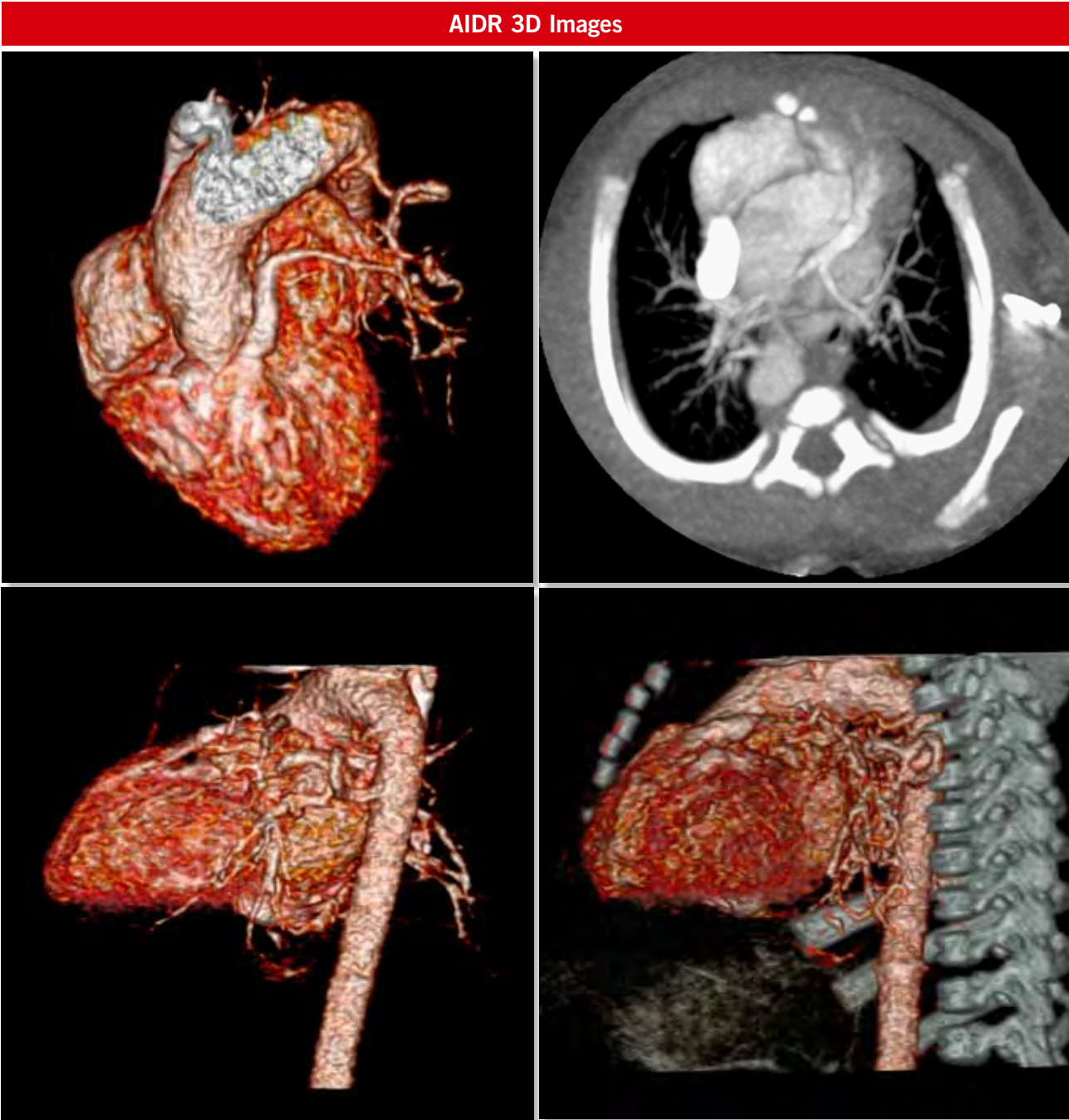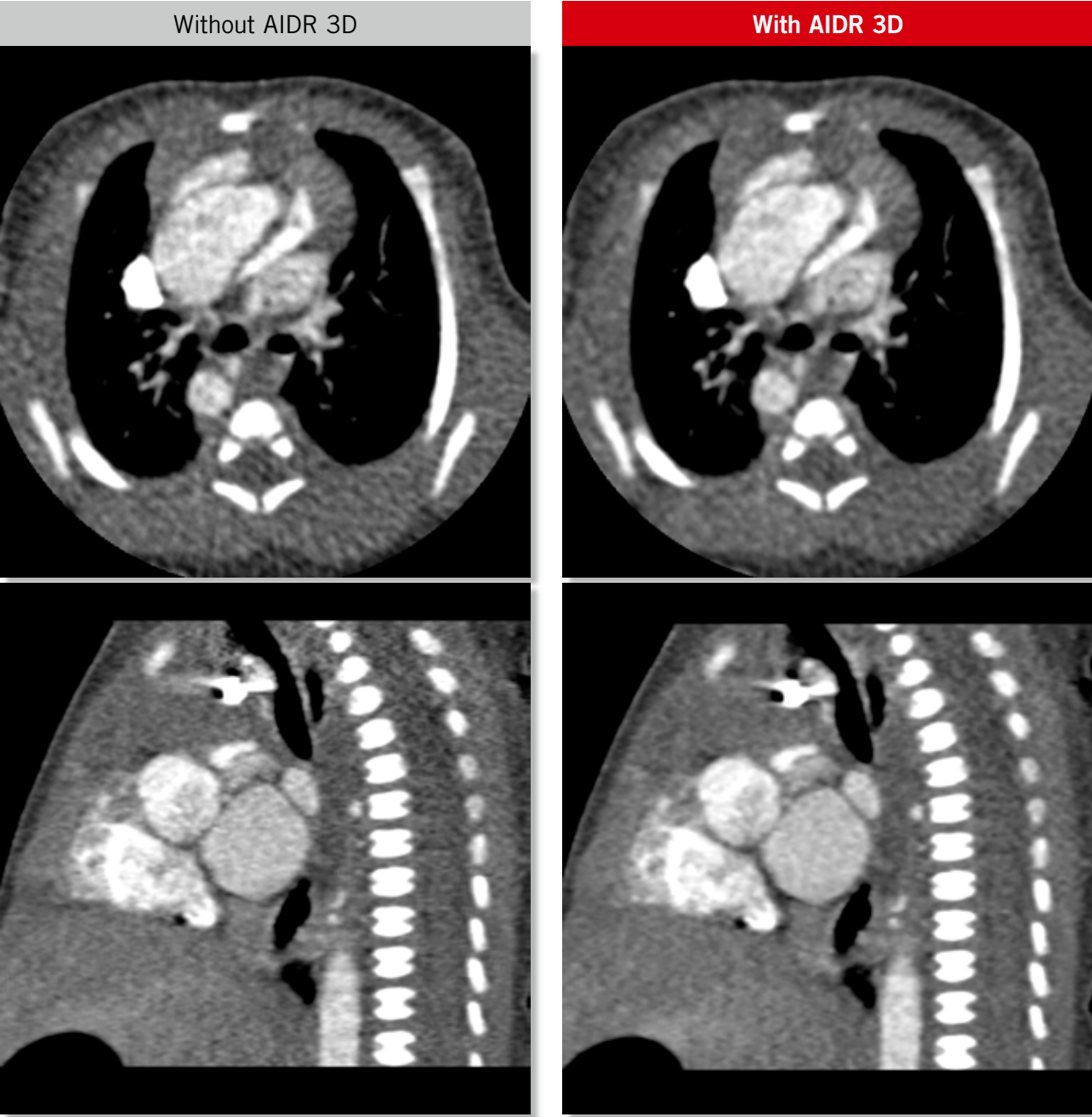
Tetralogy of Fallot

Scan Mode	Collimation	Pitch	kVp	mAs	Rotation time (s)	Scan range (mm)	Dose Reduction	CTDI vol (mGy)	DLP (mGy·cm)	Effective Dose (mSv)	K
Volume	0.5 mm x 160	na	80	100	0.35	80	AIDR 3D Standard	0.8	6.8	0.27	0.039

Clinical Description:

This is a 1-day-old baby with Tetralogy of Fallot. A CT scan of the heart and great vessels was requested to visualize the collaterals from the aorta. The patients heart rate was 145 BPM during the scan.

The main pulmonary trunk is extremely narrowed, with collateral supply arising from the aorta. The use of AIDR 3D allowed the dose to be reduced to just 0.27 mSv.





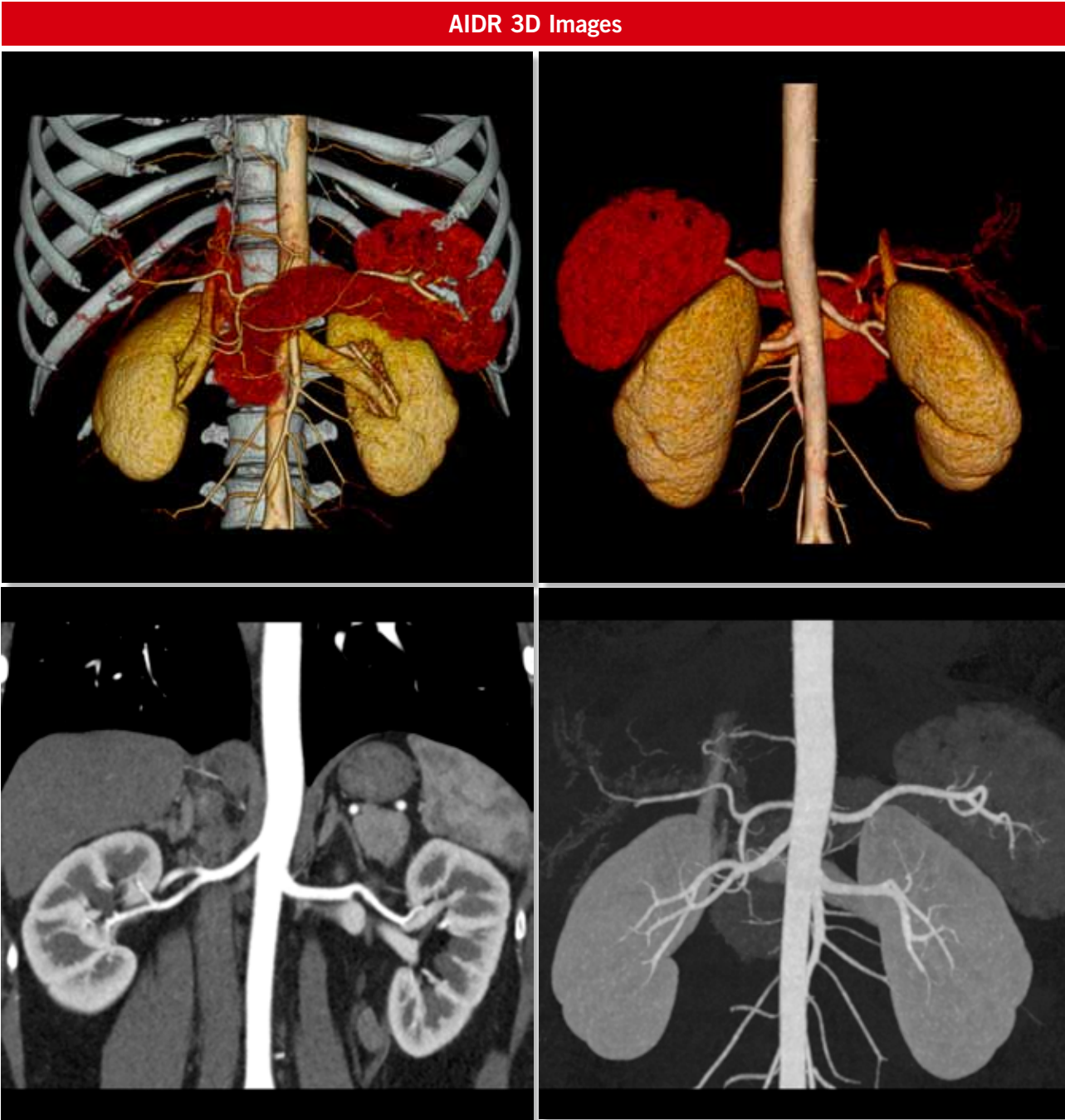
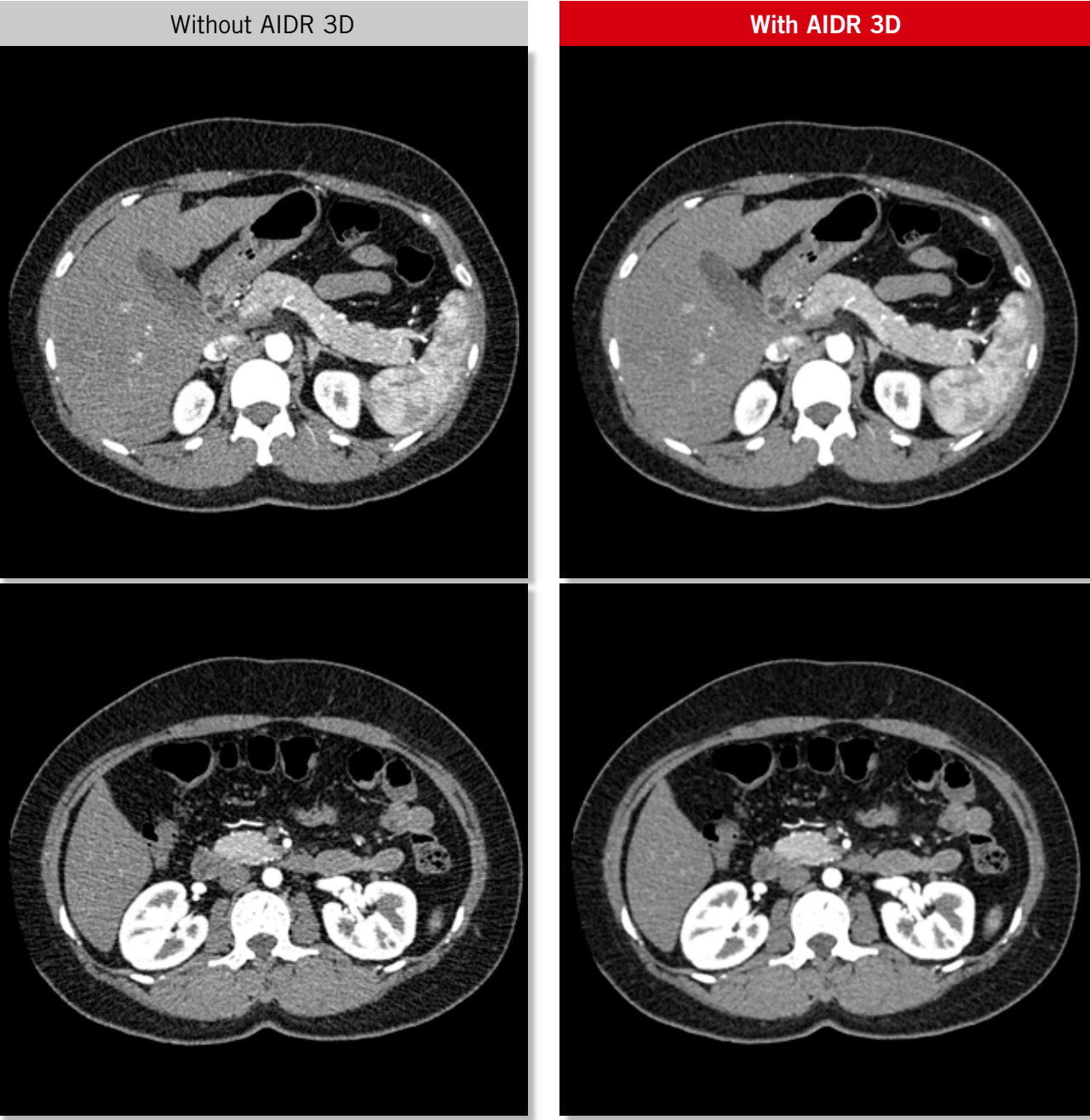
Renal CT Angiogram

Scan Mode	Collimation	Pitch	kVp	mAs	Rotation time (s)	Scan range (mm)	Dose Reduction	CTDI vol (mGy)	DLP (mGy·cm)	Effective Dose (mSv)	K
Helical	0.5 mm x 80	0.81	100	<sup>SURE</sup> Exposure Standard	0.5	219	AIDR 3D Standard	4.8	127.1	1.9	0.015

Clinical Description:

This 32-year-old woman with a BMI of 23 was sent for evaluation as a renal donor.

The kidneys are normal in size, shape, and outline and each kidney is supplied by a single renal artery. No evidence of accessory or polar renal arteries is seen. The use of AIDR 3D integrated into <sup>SURE</sup>Exposure 3D ensures excellent image quality at the lowest possible dose.



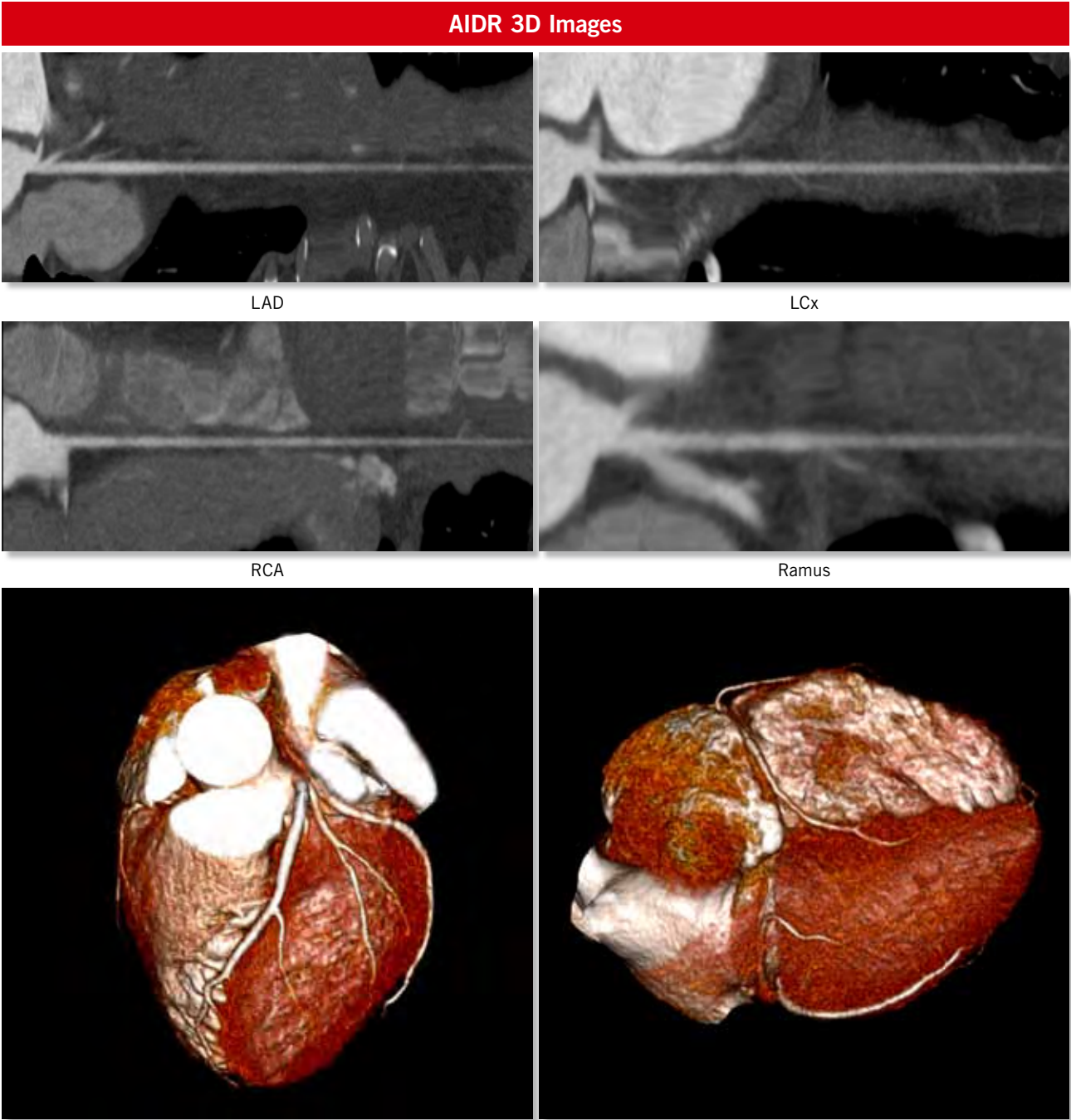
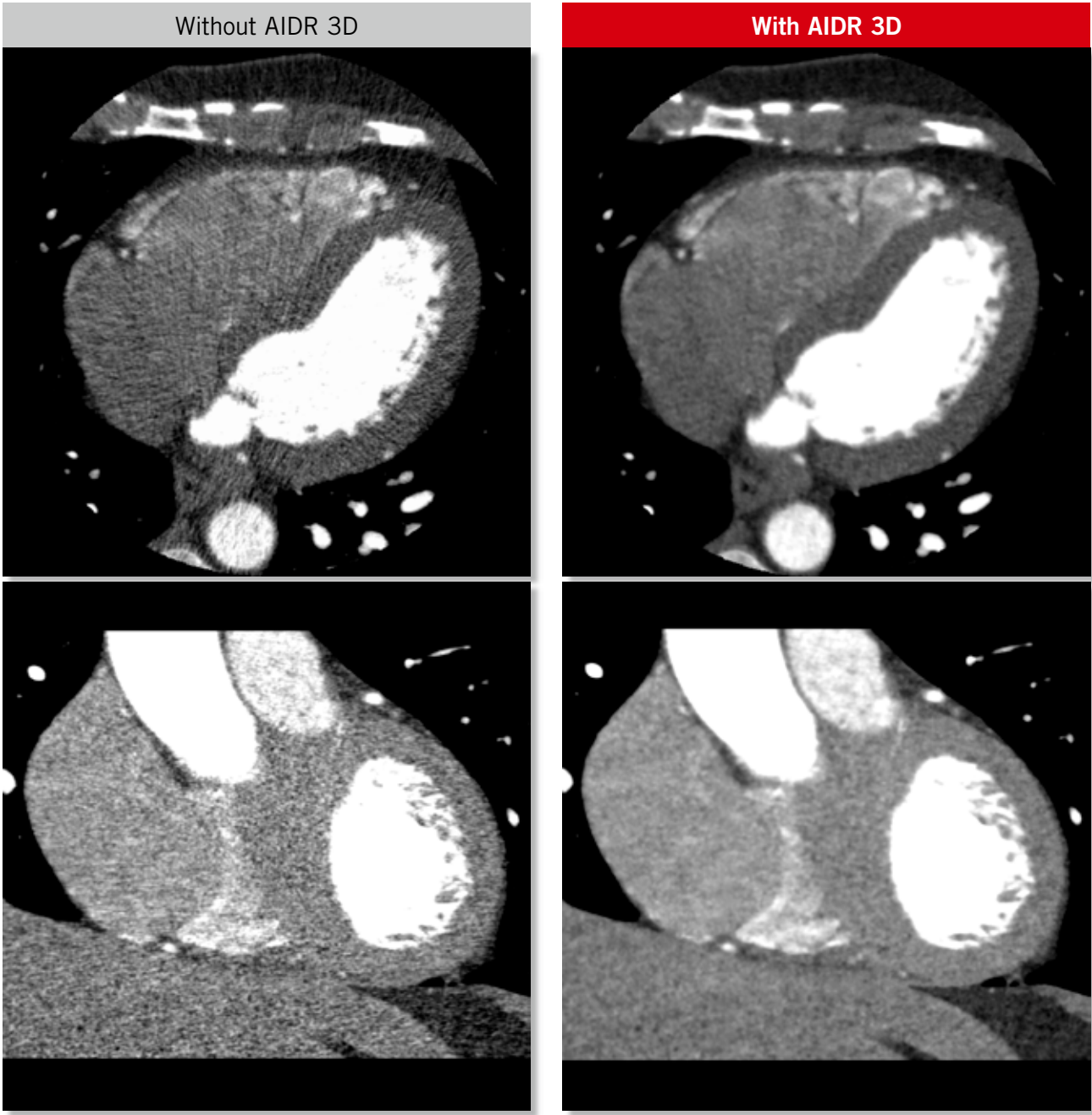


Chest Pain

Scan Mode	Collimation	Pitch	kVp	mAs	Rotation time (s)	Scan range (mm)	Dose Reduction	CTDI vol (mGy)	DLP (mGy-cm)	Effective Dose (mSv)	K
Volume	0.5 mm x 256	na	100	<sup>SURE</sup> Exposure Cardiac	0.35	128	AIDR 3D Standard	6.2	79.9	1.1	0.014

Clinical Description:

This 50-year-old man with a BMI of 25 presented to the emergency department with chest pain. Coronary artery disease could be ruled out based on the findings of this study performed with a dose of just 1.1 mSv. <sup>SURE</sup>Exposure 3D Adaptive in combination with AIDR 3D allows low-dose examinations to be performed routinely.





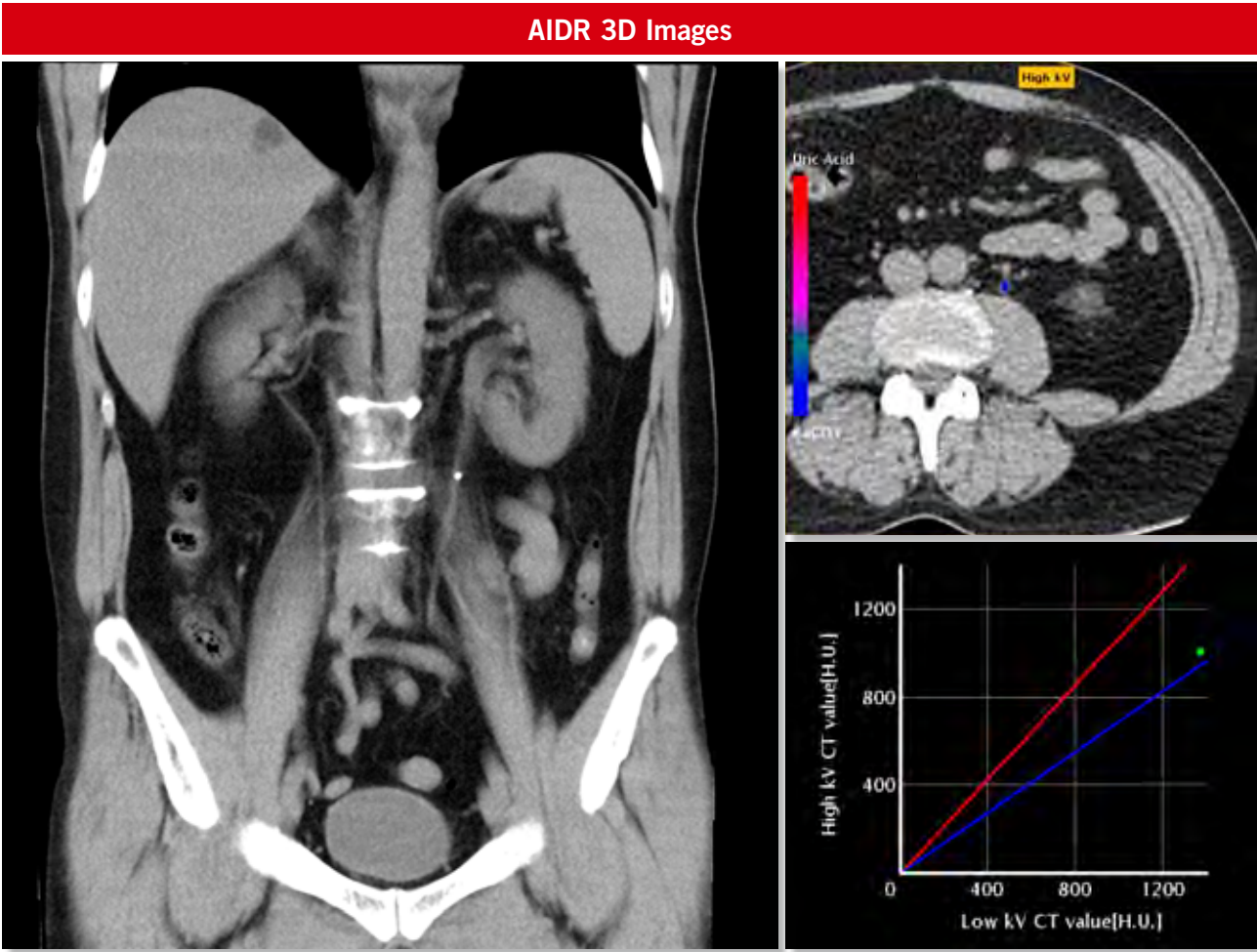
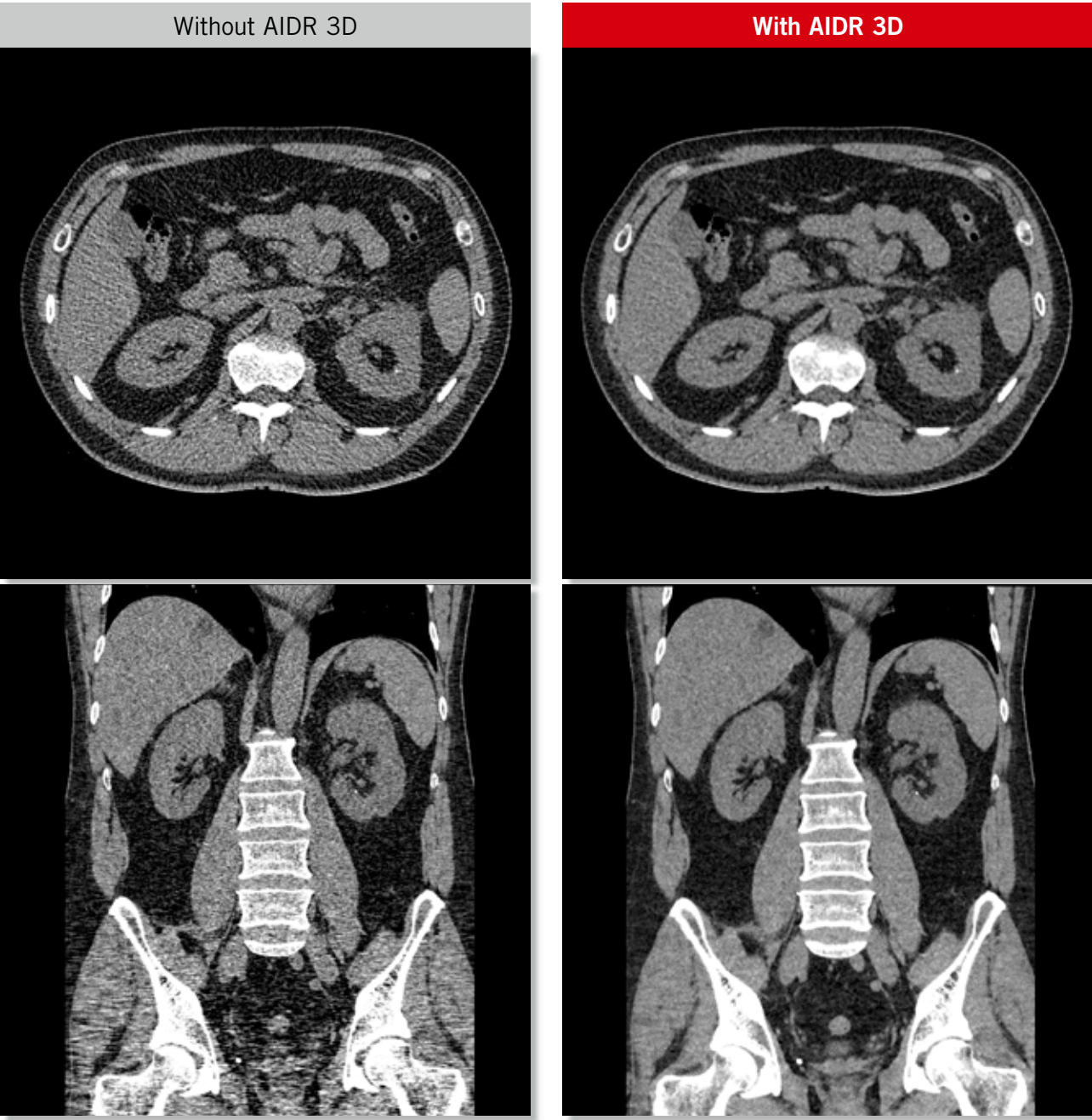
Renal Colic

Scan Mode	Collimation	Pitch	kVp	mAs	Rotation time (s)	Scan range (mm)	Dose Reduction	CTDI vol (mGy)	DLP (mGy-cm)	Effective Dose (mSv)	K
Helical	0.5 mm x 80	0.81	120	SURE <sup>®</sup> Exposure Low Dose	0.5	455	AIDR 3D Standard	2.9	148.7	2.2	0.015

Clinical Description:

This 47-year-old man with a BMI of 29 presented to the emergency department with renal colic.

A single calculus is seen in the mid left ureter. Further analysis with a Dual Energy scan showed the material composition of the stone to be calcific.





Associate Professor Sujith Seneviratne  
Co-director Cardiac CT, Monash Heart  
Australia

Coronary artery CT angiography has become a routinely requested examination in our institution since the introduction of the Aquilion ONE CT system in September 2008. For the investigation of patients with a low to intermediate probability of coronary artery disease, the Aquilion ONE provides examinations with excellent image quality in almost all patients, including patients with cardiac arrhythmias.

The introduction of iterative reconstruction techniques on our system instantly enabled scans to be performed with approximately 50% less radiation dose, producing images with superior diagnostic quality. At these new low-dose settings, AIDR 3D eliminates streak artifacts that would be present with standard filtered backprojection reconstruction and has allowed us to use 80 or 100 kV in a significant proportion of our patients. An additional benefit of acquiring the scans with a lower beam energy is an increase in iodine attenuation, resulting in an improved contrast-to-noise ratio. Therefore, there is the potential to reduce the contrast medium volume, and in some cases we have already seen great results with a bolus injection of just 40 mL. The combination of lower tube voltage with lower contrast dose will be a focus for future research made possible with AIDR 3D.

There is no doubt that coronary artery imaging with CT is a robust examination in appropriate patient groups, and now with a dramatic reduction of both radiation and contrast dose, the acceptance of this imaging test is only going to grow.



Prof. Alain Blum  
Head of Radiology - CHU Nancy  
France

The Aquilion ONE CT scanner in our department sees a lot of sick inpatients and emergency patients for chest, abdomen, and pelvis studies. Due to the condition of these patients, they most often need to be scanned with the arms down and sometimes with metallic immobilization or monitoring devices within the scan field. As such, these patient scans are susceptible to streak artifacts, which were previously reduced by the use of a higher than normal X-ray exposure.

AIDR 3D was installed on our Aquilion ONE system in July 2011. During the very first week, we were able to reduce our overall doses by more than 70%. The level of dose reduction was well beyond what we expected. The AIDR 3D images look very similar to those reconstructed with classic filtered backprojection. We have not noticed any plastic effect or loss of spatial resolution. Therefore, everyone was immediately confident using these images for diagnostic purposes. The icing on the cake is the dramatic reduction of streak and beam hardening artifacts, bringing significant improvements to image quality in many situations (hip, shoulder), thus leading to an additional dose reduction with no compromise in image quality.

AIDR 3D is a fine solution to dramatically reduce X-ray dose and improve image quality. It should be immediately adopted when installed on your Toshiba CT system.



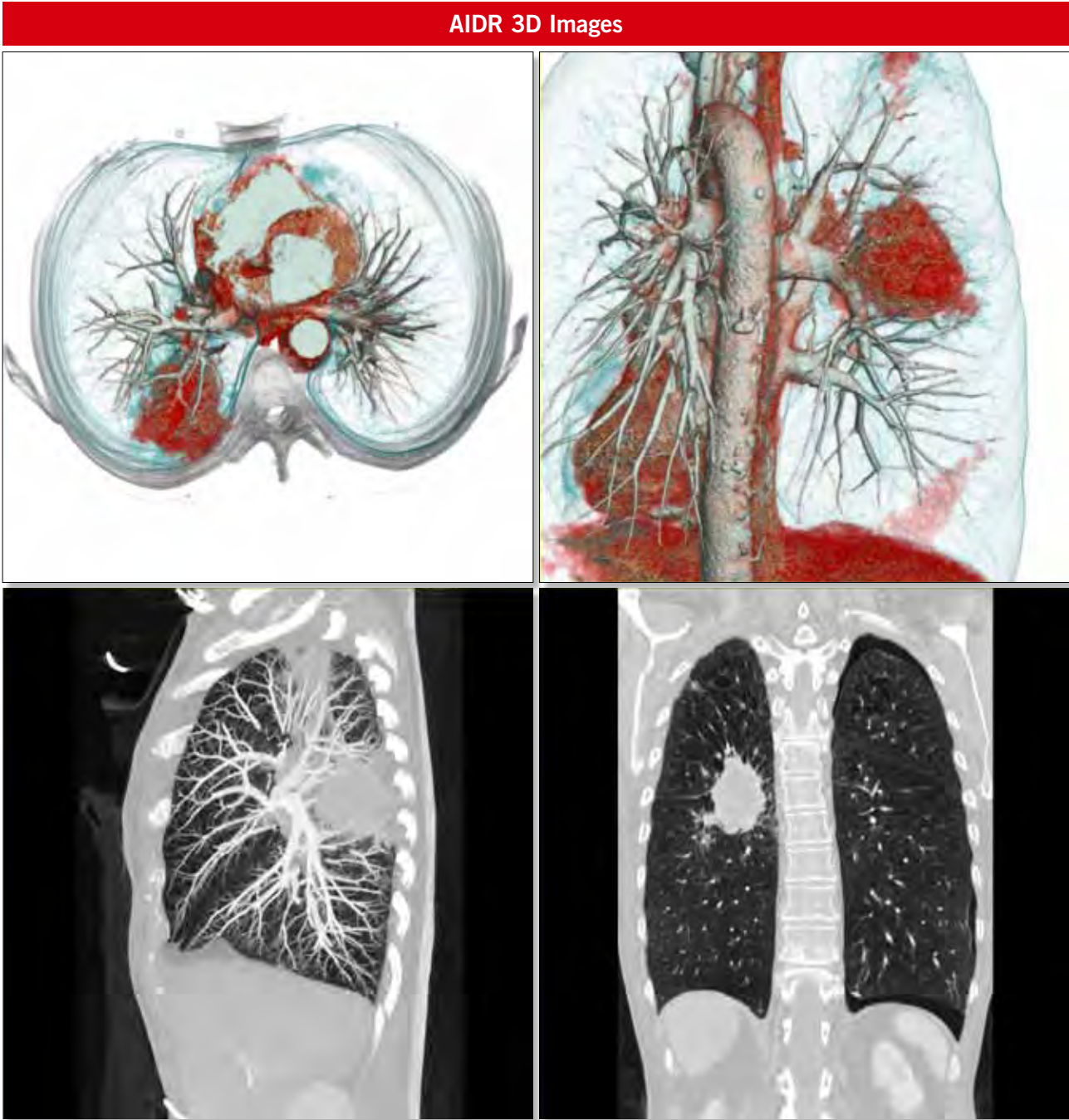
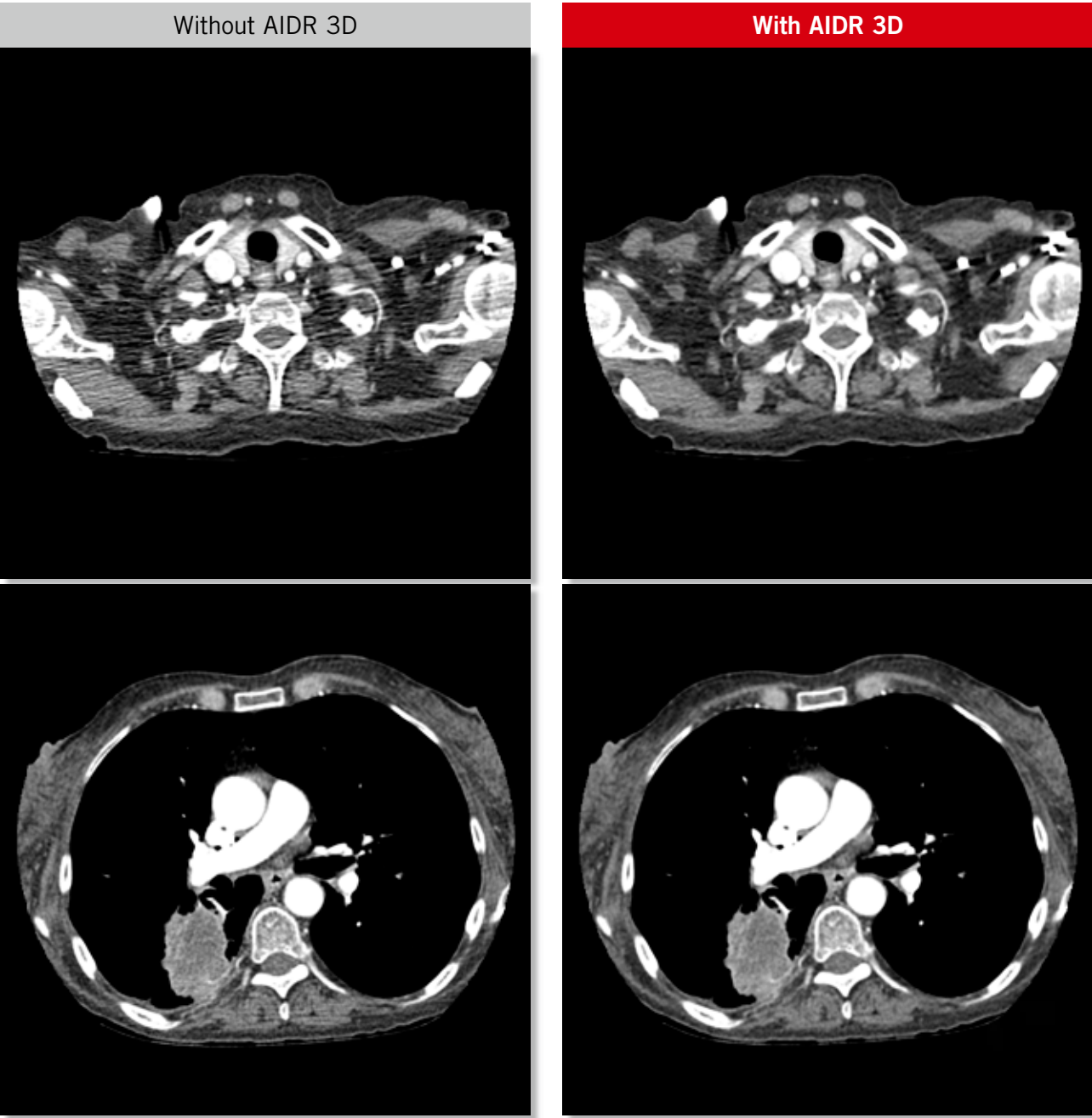
Lung Tumor

Scan Mode	Collimation	Pitch	kVp	mAs	Rotation time (s)	Scan range (mm)	Dose Reduction	CTDI vol (mGy)	DLP (mGy-cm)	Effective Dose (mSv)	K
Helical	0.5 mm x 80	1.39	120	<sup>SURE</sup> Exposure Standard	0.5	360	AIDR 3D Standard	2.7	116.0	1.6	0.014

Clinical Description:

This is a 62-year-old woman with a BMI of 20.

A large primary lung tumor is demonstrated in the right lung. A second smaller lesion is seen in the right upper lobe, presumably a metastasis. In addition, pneumothorax is noted in the left hemithorax.

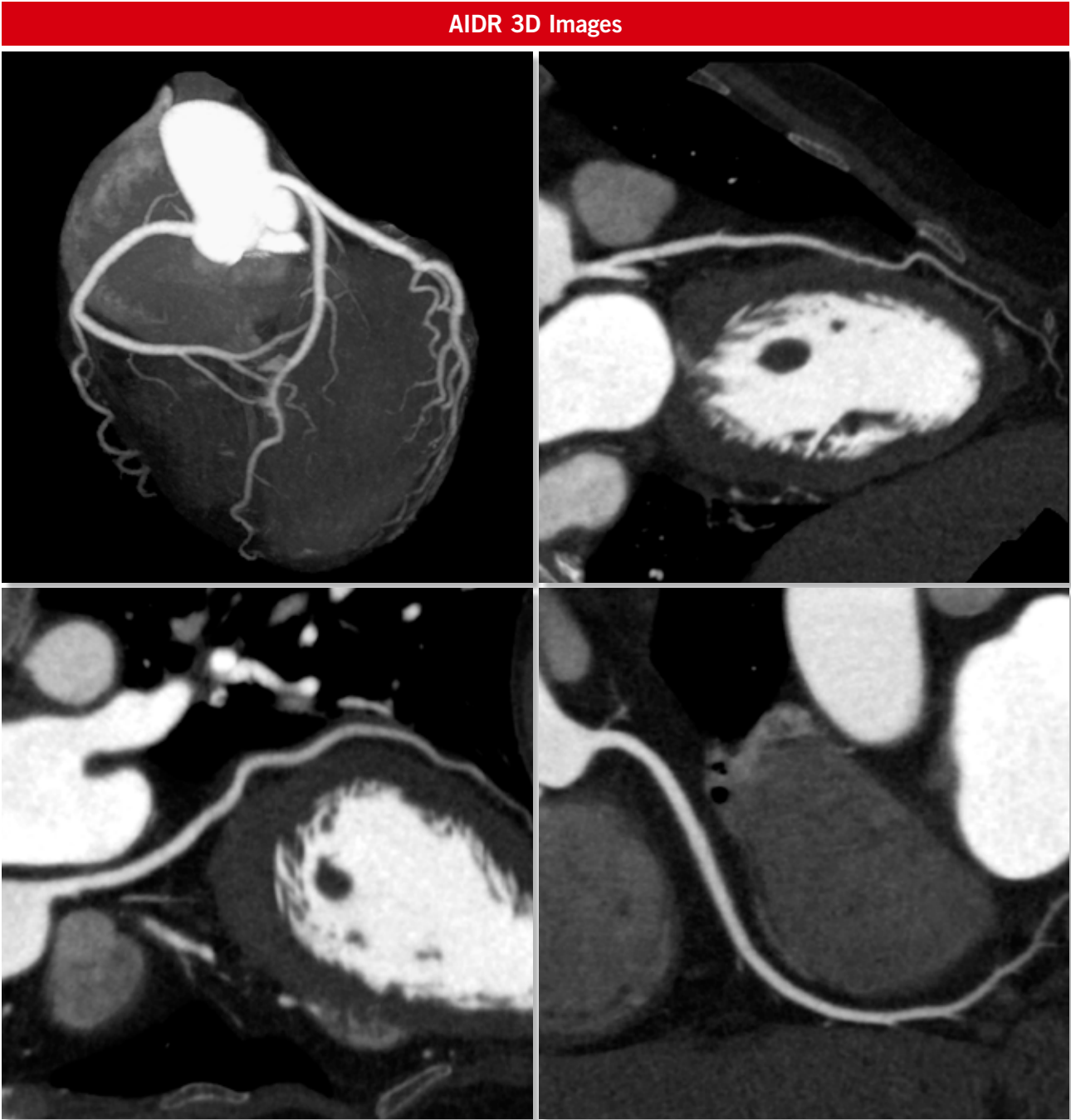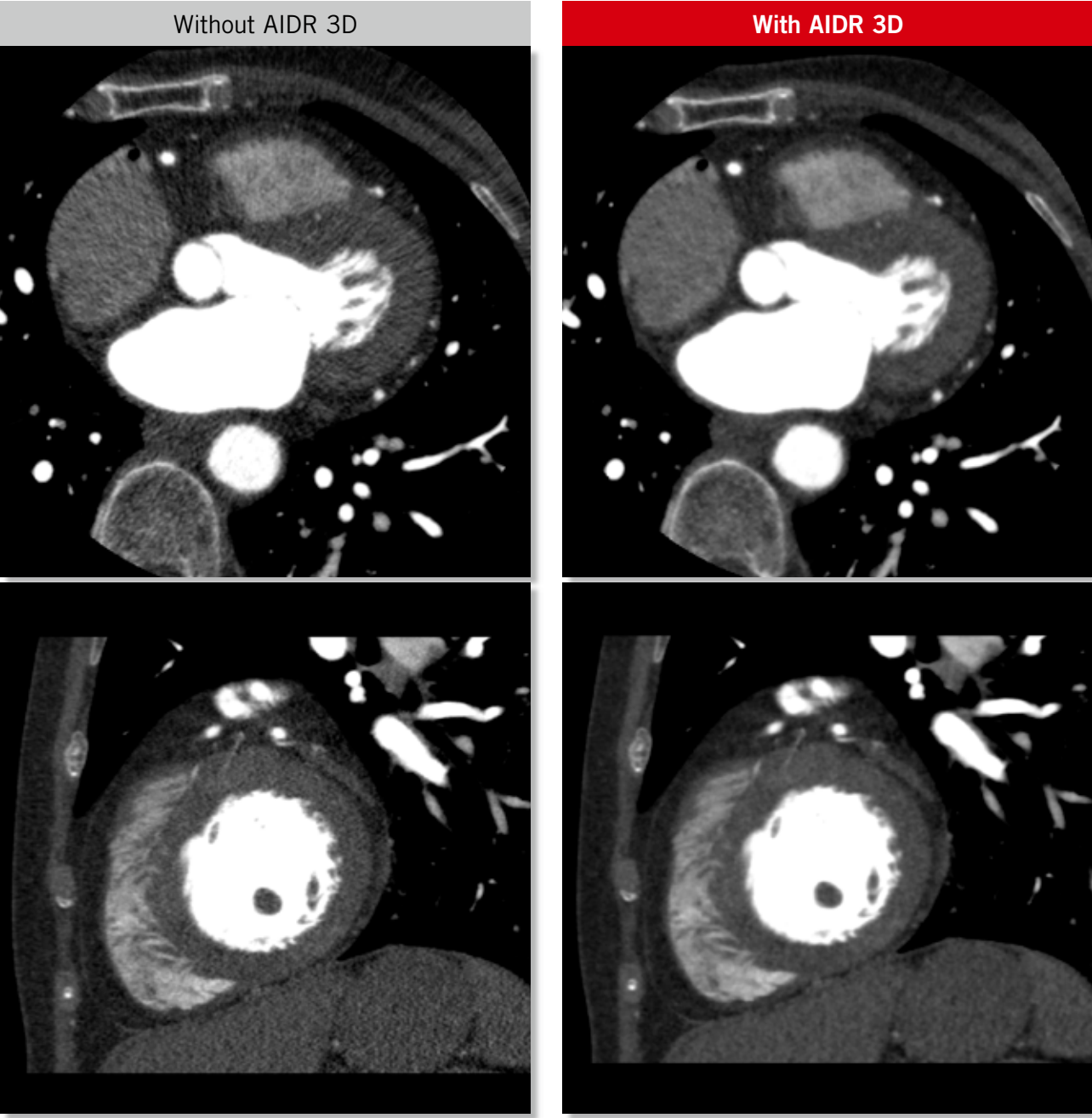


Myocardial Bridging

Scan Mode	Collimation	Pitch	kVp	mAs	Rotation time (s)	Scan range (mm)	Dose Reduction	CTDI vol (mGy)	DLP (mGy-cm)	Effective Dose (mSv)	K
Volume	0.5 mm x 256	na	100	<sup>SURE</sup> Exposure Cardiac	0.35	128	AIDR 3D Standard	5.2	66.0	0.9	0.014

Clinical Description:

This 70-year-old woman with a BMI of 19 presented to the emergency department with chest pain. A partial myocardial bridge is seen in the mid LAD. The patient was discharged after a normal troponin test was confirmed.





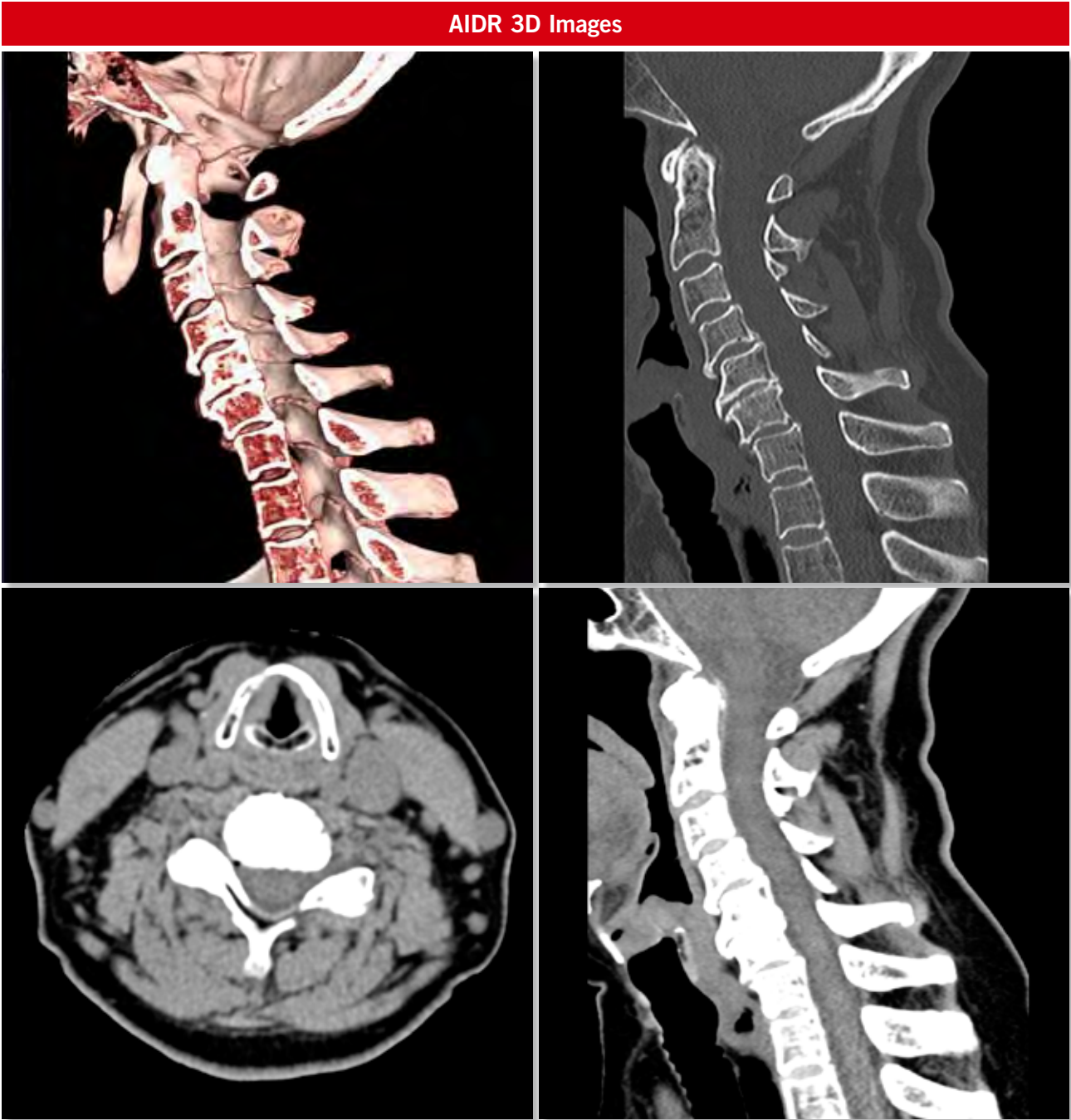
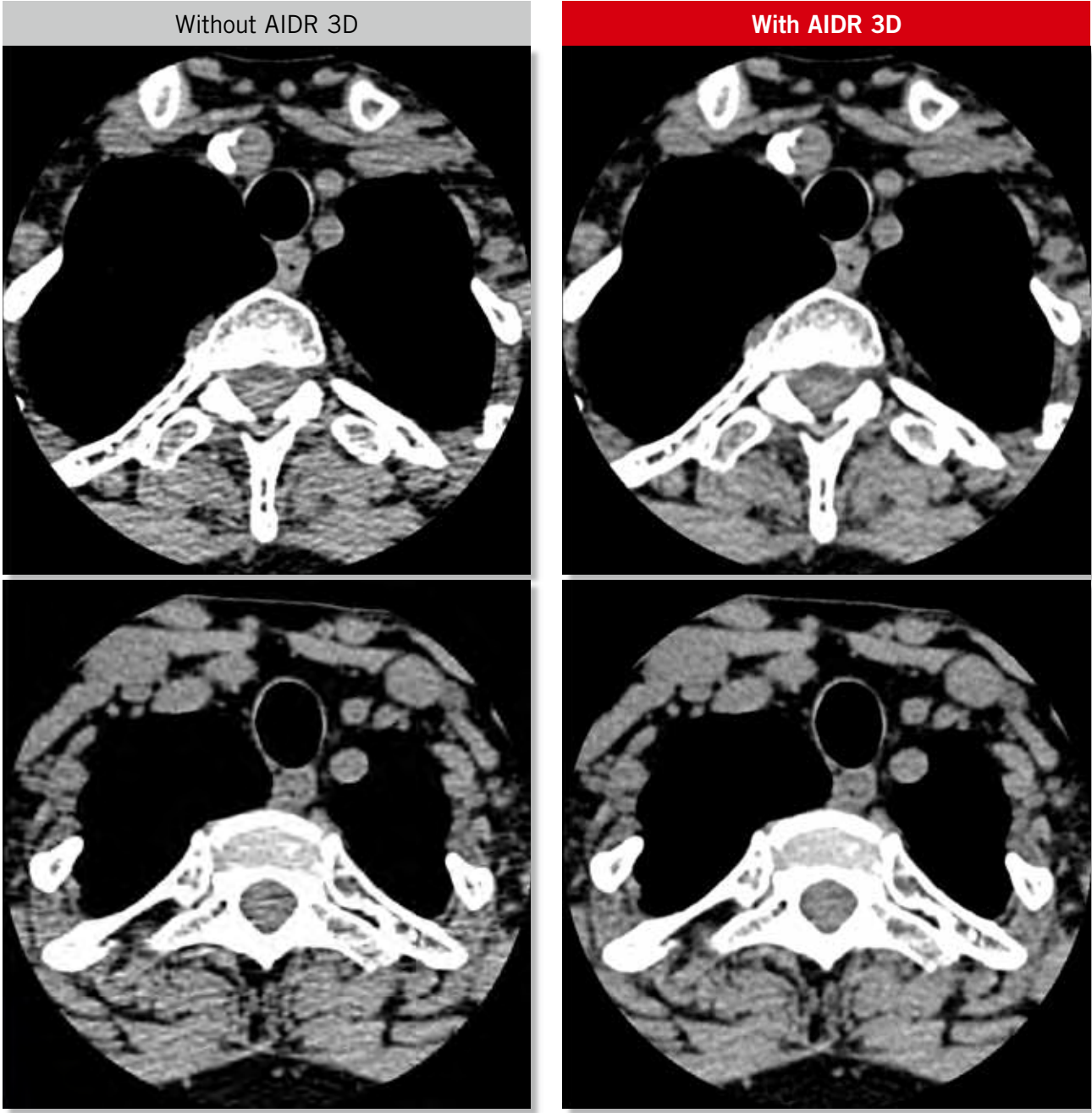
Cervical Spine

Scan Mode	Collimation	Pitch	kVp	mAs	Rotation time (s)	Scan range (mm)	Dose Reduction	CTDI vol (mGy)	DLP (mGy-cm)	Effective Dose (mSv)	K
Helical	0.5 mm x 80	0.634	120	<sup>SURE</sup> Exposure Quality	0.5	172	AIDR 3D Standard	8.3	179.2	1.1	0.0059

Clinical Description:

This 71-year-old woman with a BMI of 28 presented with an axillary mass and neck pain. A CT scan was requested to rule out cervical metastases.

The cervical spine is degenerative with osteophytic lipping. Excellent images were obtained with AIDR 3D at a dose of just 1.1 mSv.

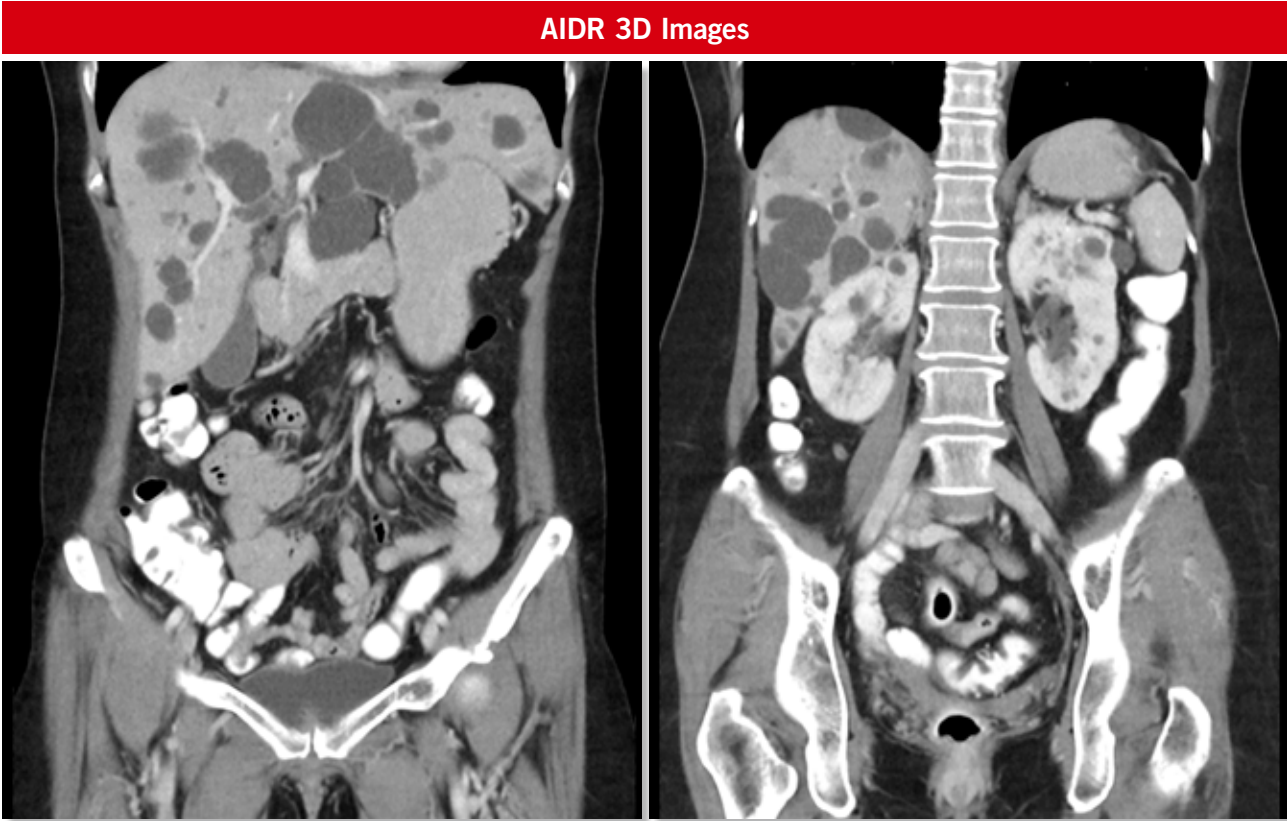
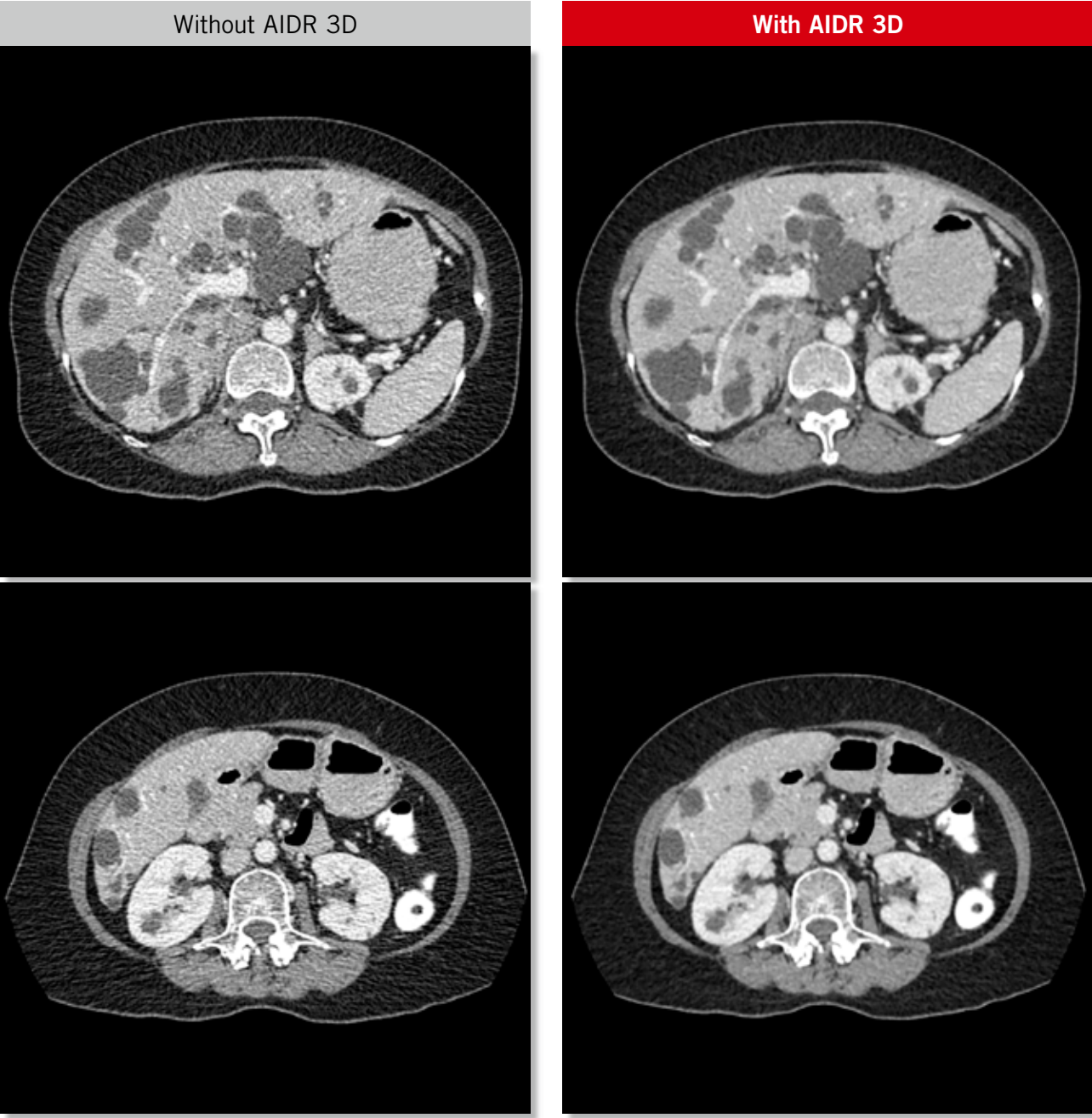


Polycystic Disease

Scan Mode	Collimation	Pitch	kVp	mAs	Rotation time (s)	Scan range (mm)	Dose Reduction	CTDI vol (mGy)	DLP (mGy·cm)	Effective Dose (mSv)	K
Helical	0.5 mm x 80	0.81	120	SURE Exposure Standard	0.5	370	AIDR 3D Standard	4.6	190.1	2.85	0.015

Clinical Description:

This 57-year-old woman with a BMI of 23.6 was sent for a CT scan of the abdomen and pelvis. The images demonstrate extensive polycystic disease with multiple cysts in the liver and kidneys. AIDR 3D eliminates streak artifacts even with low-dose scan conditions.





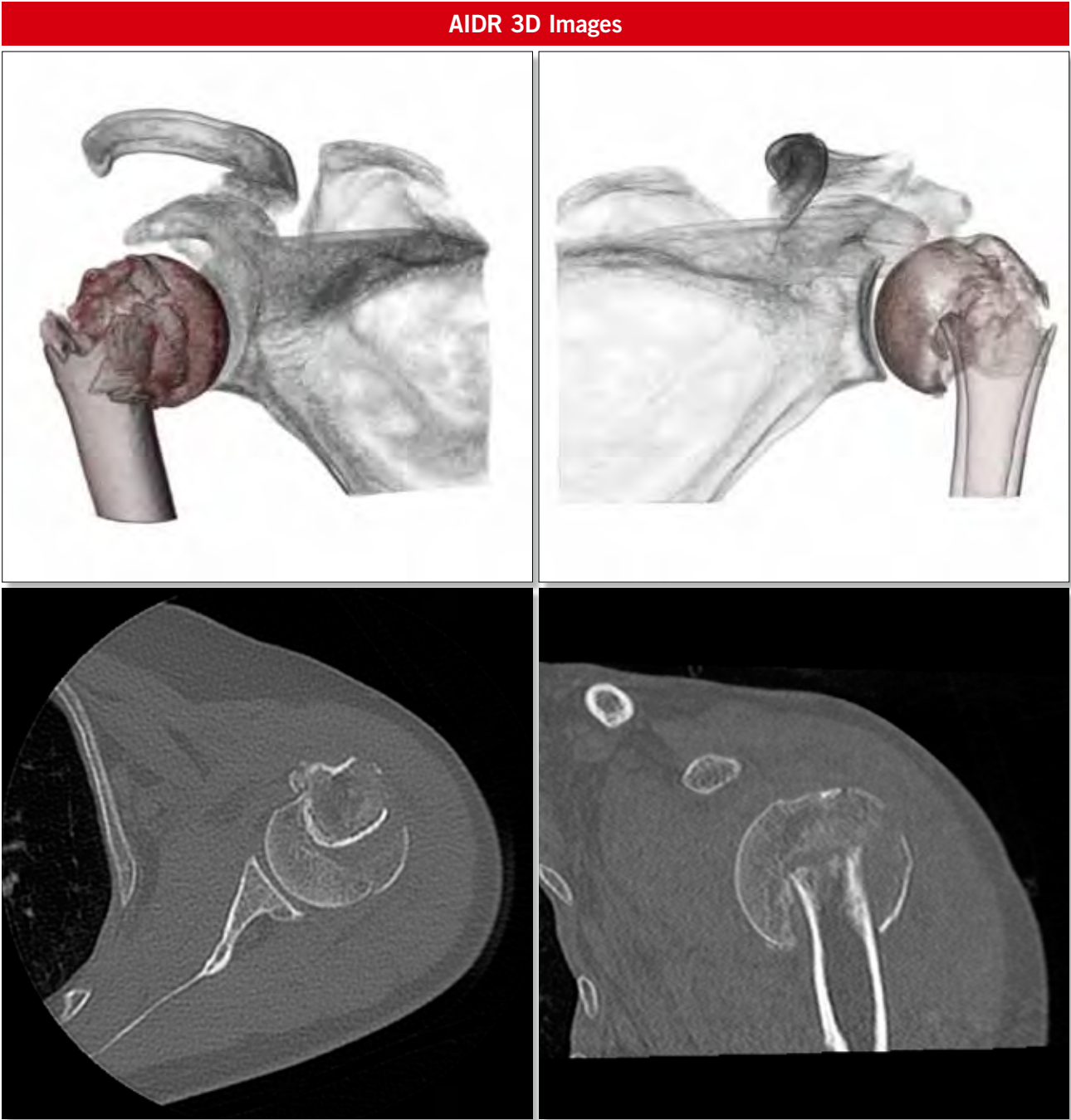
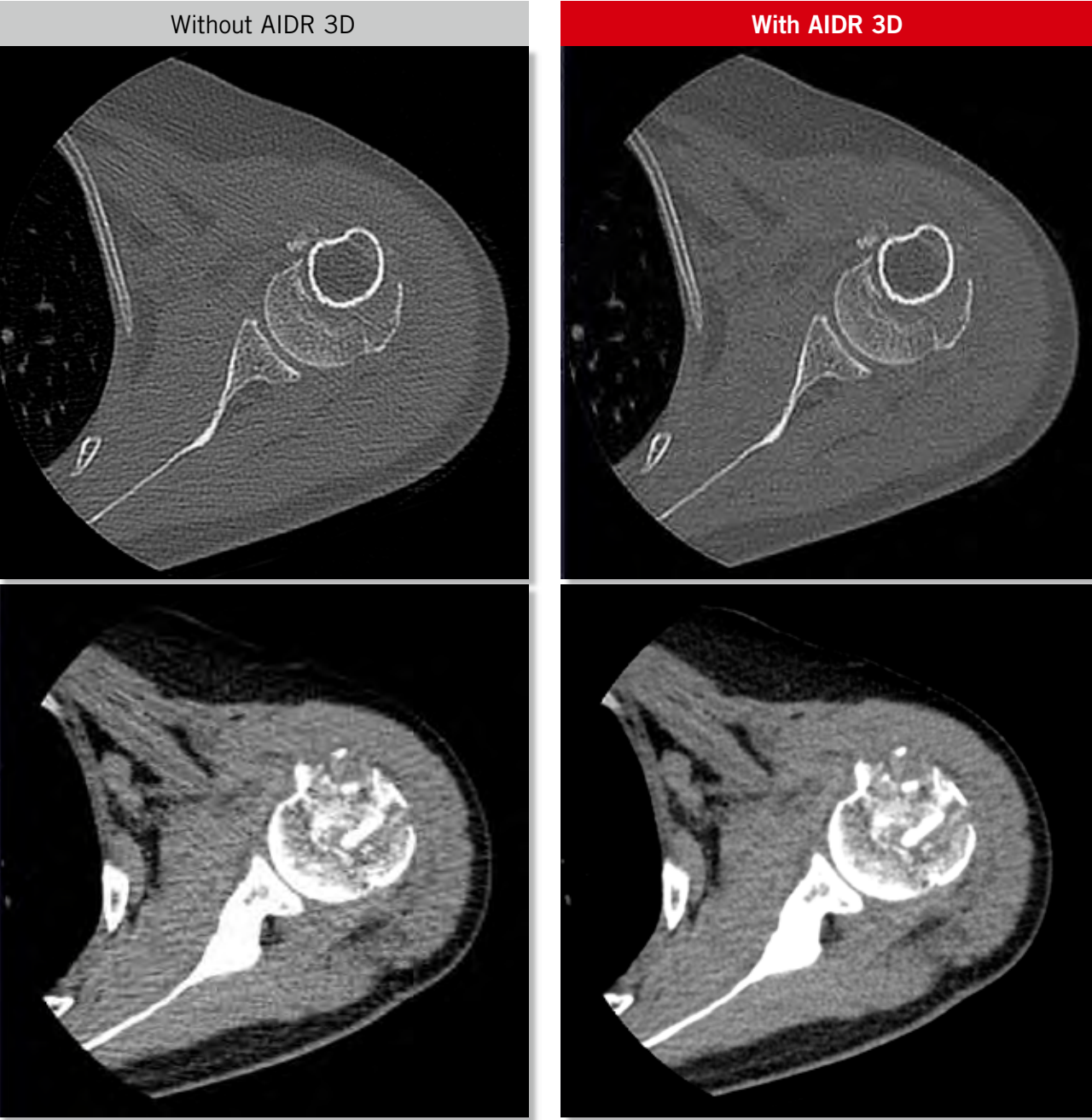
Impacted Fracture

Scan Mode	Collimation	Pitch	kVp	mAs	Rotation time (s)	Scan range (mm)	Dose Reduction	CTDI vol (mGy)	DLP (mGy-cm)	Effective Dose (mSv)	K
Volume	0.5 mm x 240	na	120	<sup>SURE</sup> Exposure Quality	0.5	120	AIDR 3D Standard	8.8	105.3	1.5	0.014

Clinical Description:

This 57-year-old man with a BMI of 25 fell off a ladder.

There is an impacted fracture involving the neck of the right humerus and the humeral head.





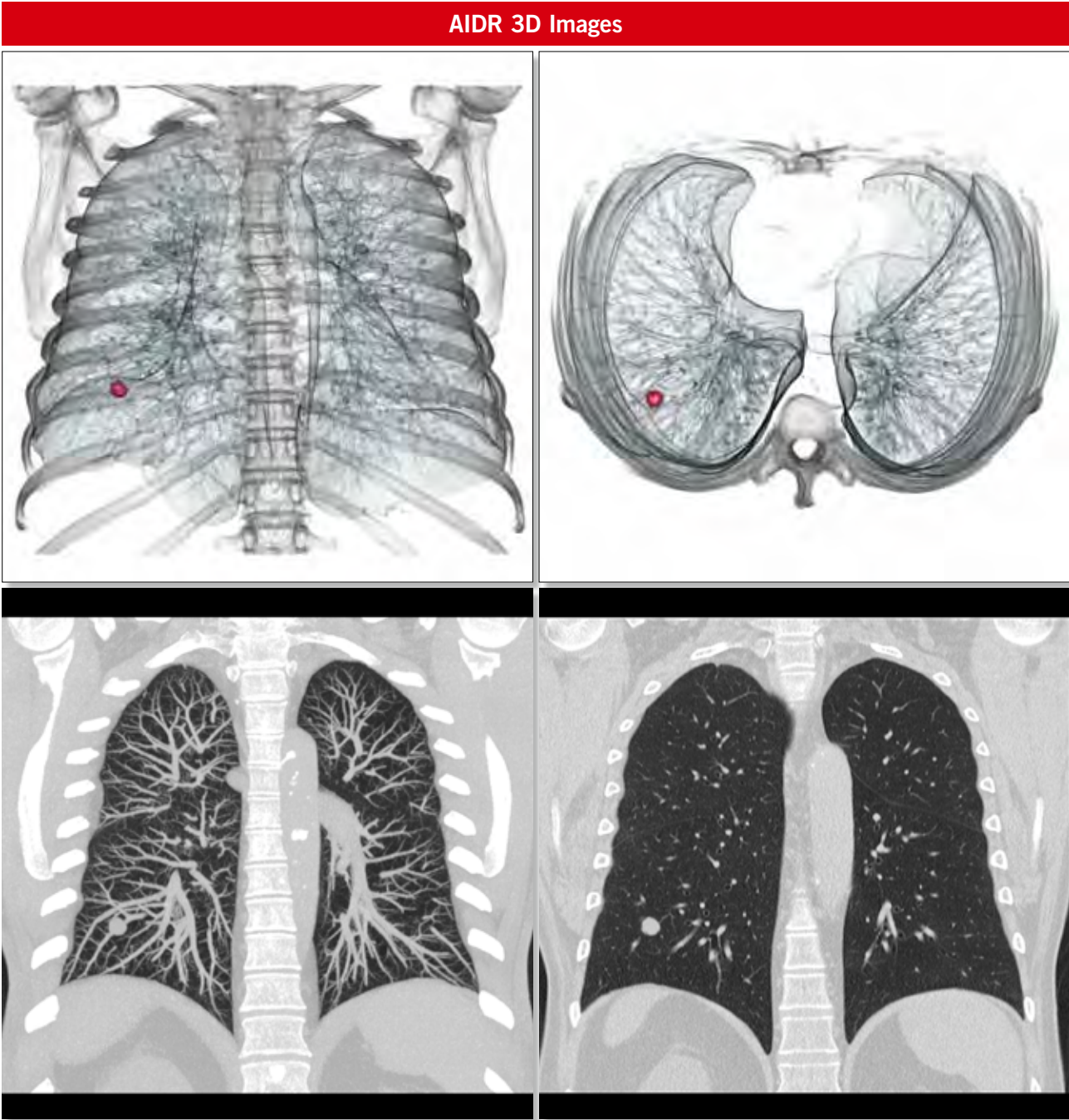
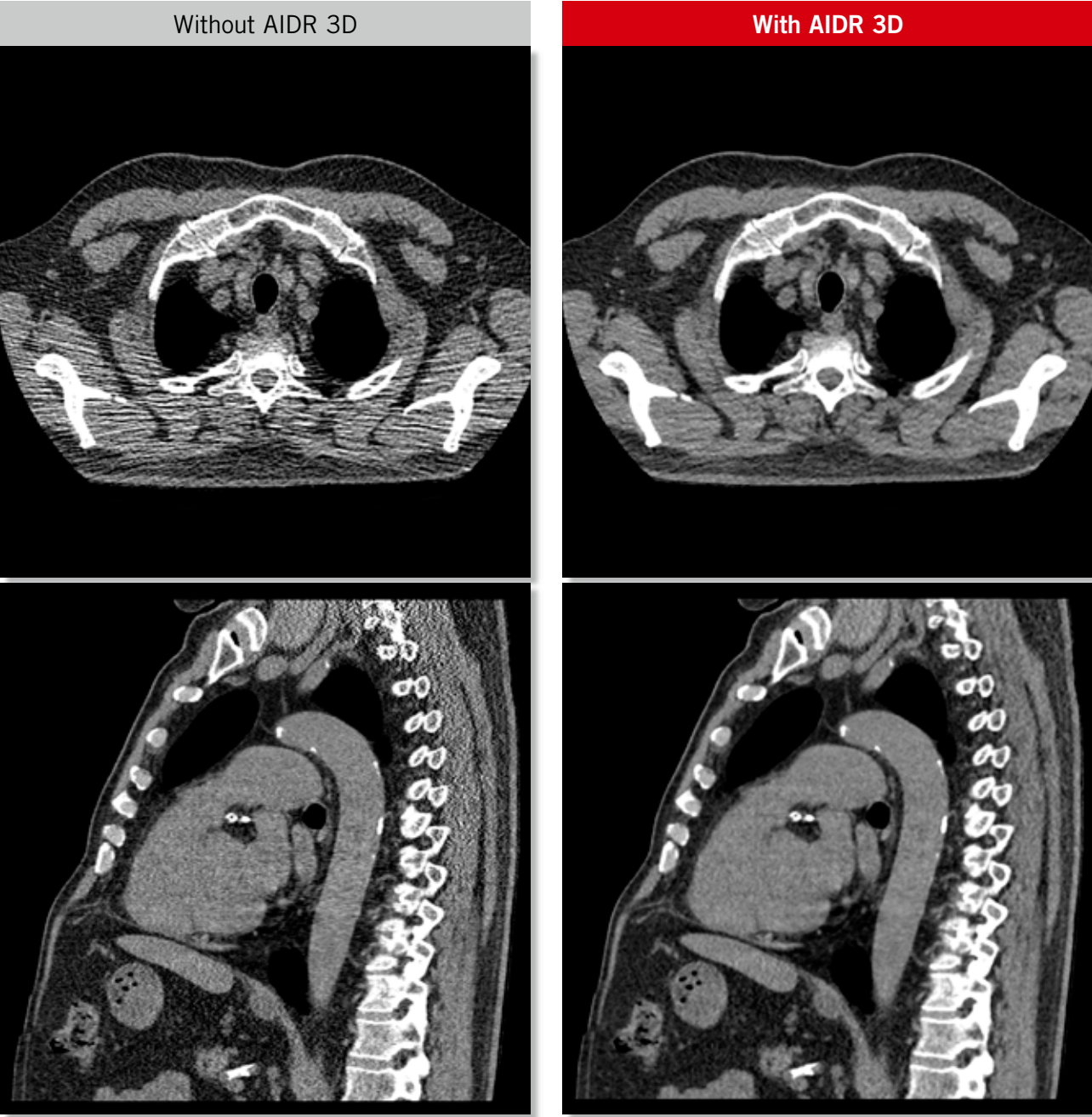
Lung Metastasis

Scan Mode	Collimation	Pitch	kVp	mAs	Rotation time (s)	Scan range (mm)	Dose Reduction	CTDI vol (mGy)	DLP (mGy-cm)	Effective Dose (mSv)	K
Helical	0.5 mm x 80	1.39	120	<sup>SURE</sup> Exposure Standard	0.5	315	AIDR 3D Standard	7.0	264.8	3.7	0.014

Clinical Description:

This 65-year-old man with a BMI of 34 and a known primary bone carcinoma was scheduled for a CT scan of the chest to screen for lung metastases.

A single metastatic lesion is seen in the right lower lobe. In patients who will require multiple follow-up examinations, it is important to scan at the lowest possible dose. AIDR 3D is the new standard for routine low-dose imaging.





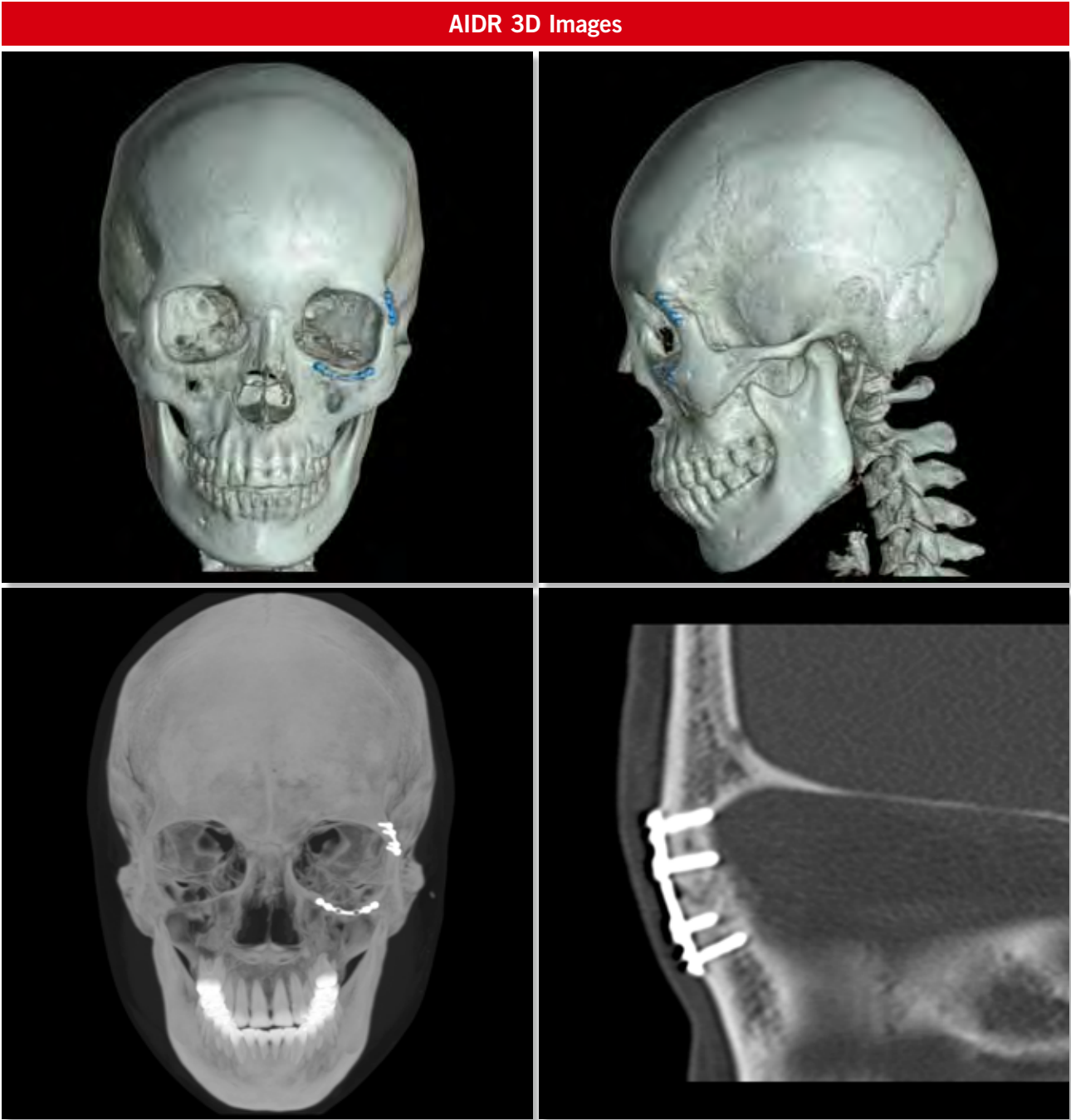
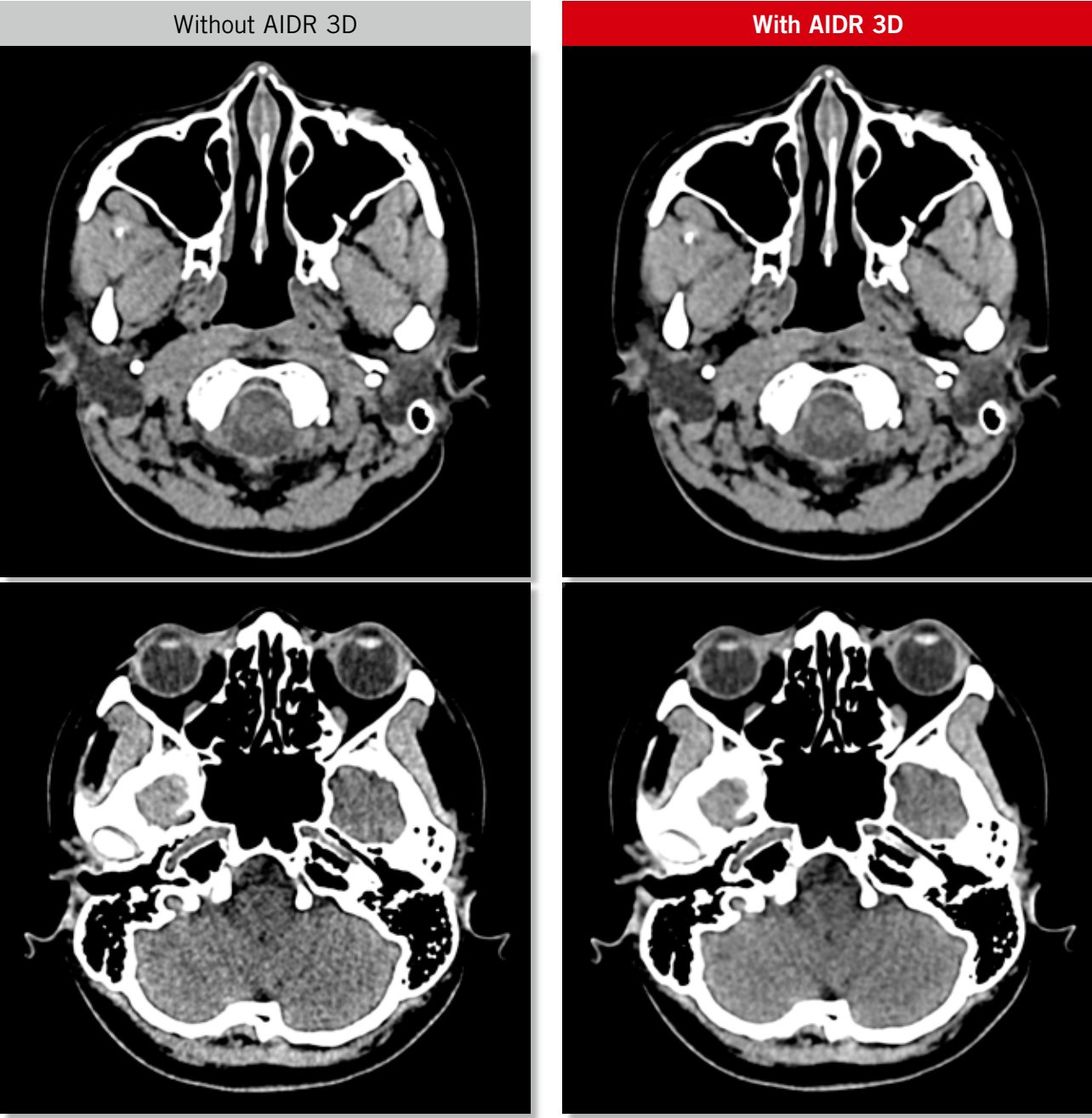
Facial Bones

Scan Mode	Collimation	Pitch	kVp	mAs	Rotation time (s)	Scan range (mm)	Dose Reduction	CTDI vol (mGy)	DLP (mGy-cm)	Effective Dose (mSv)	K
Helical	0.5 mm x 80	0.63	120	80	0.5	224	AIDR 3D Standard	16.4	404.5	1.3	0.0031

Clinical Description:

This is a 36-year-old woman with a previous orbital fracture treated by internal fixation.

The implants in the lateral and inferior walls of the left orbit show excellent positioning.



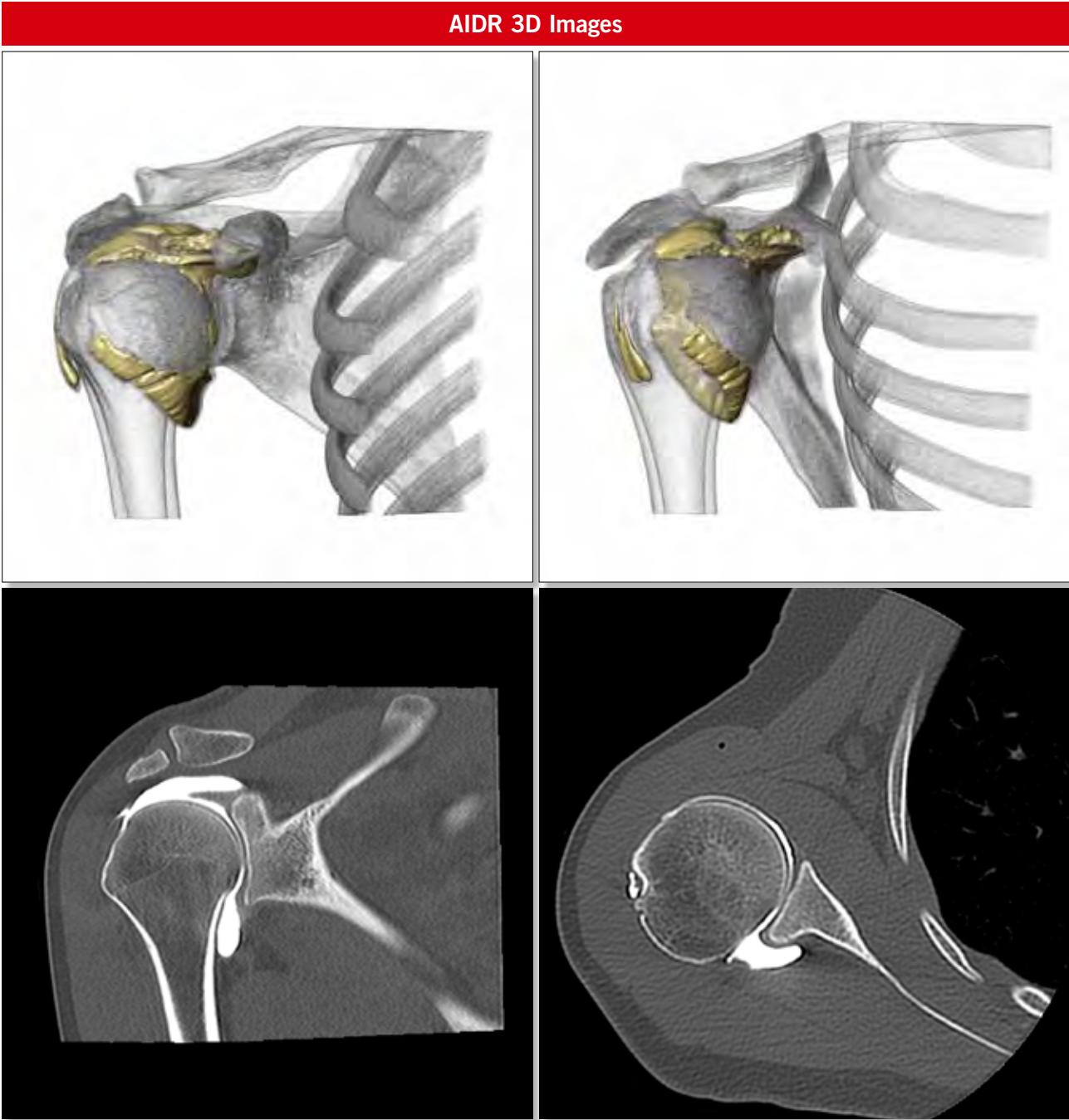
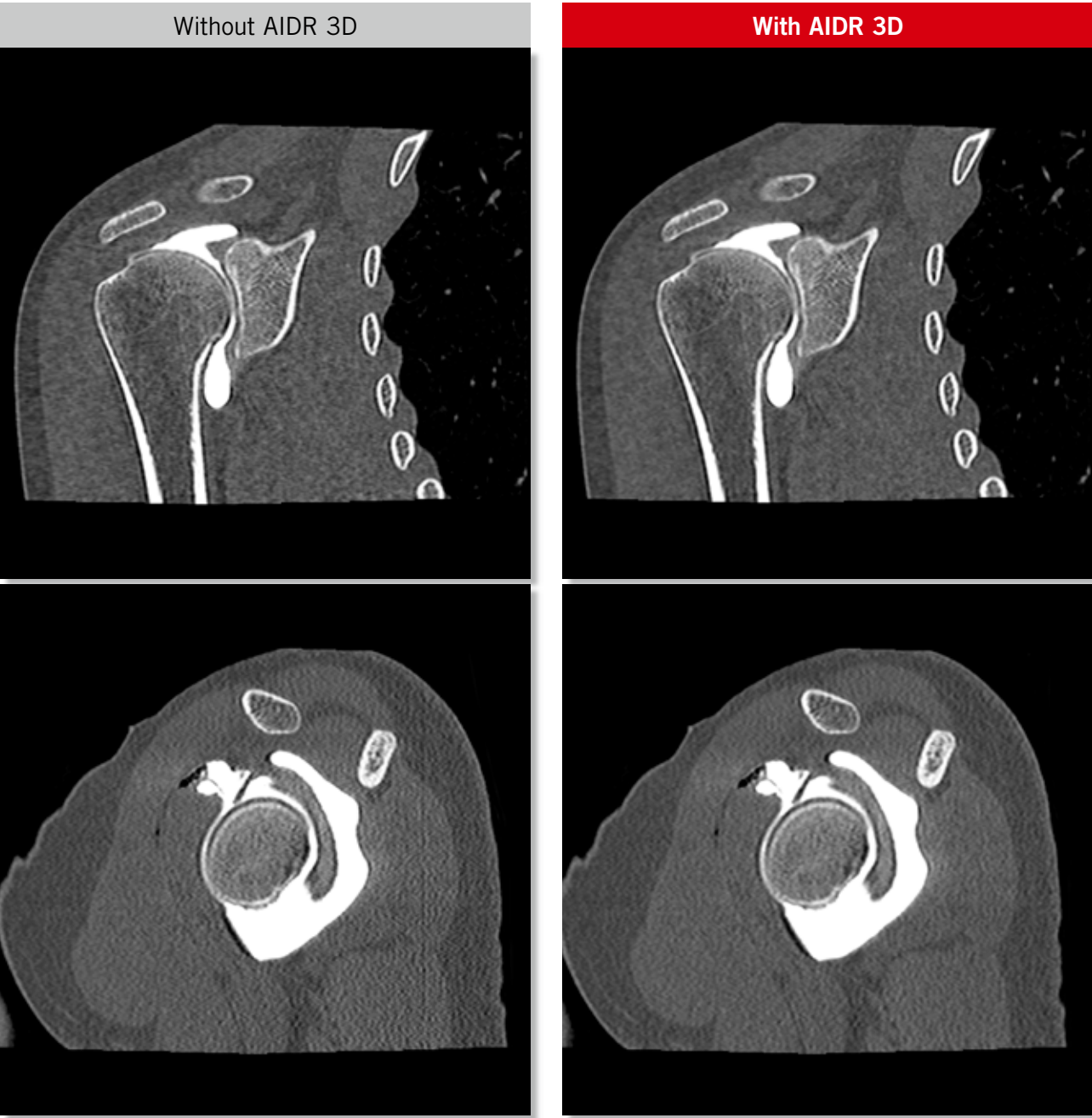Shoulder Arthrogram

Scan Mode	Collimation	Pitch	kVp	mAs	Rotation time (s)	Scan range (mm)	Dose Reduction	CTDI vol (mGy)	DLP (mGy·cm)	Effective Dose (mSv)	K
Volume	0.5 mm x 240	na	120	150	0.75	120	AIDR 3D Standard	10.5	125.4	1.8	0.014

Clinical Description:

This 24-year-old woman with a BMI of 19 was sent for CT arthrography of the right shoulder.

The detailed bone structure is completely preserved with AIDR 3D reconstruction, as demonstrated in this arthrogram of the shoulder.





CT Urography

Scan Mode	Collimation	Pitch	kVp	mAs	Rotation time (s)	Scan range (mm)	Dose Reduction	CTDI vol (mGy)	DLP (mGy-cm)	Effective Dose (mSv)	K
Helical	0.5 mm x 80	0.81	120	SURE Exposure Standard	0.5	372	AIDR 3D Standard	4.7	197.1	2.96	0.015

Clinical Description:

This 58-year-old woman with a BMI of 25 complained of right flank pain.

There is a kink in the proximal ureter, likely responsible for the slight fullness of the right pelvicalyceal system.

No mass or irregularity is identified in this region.

